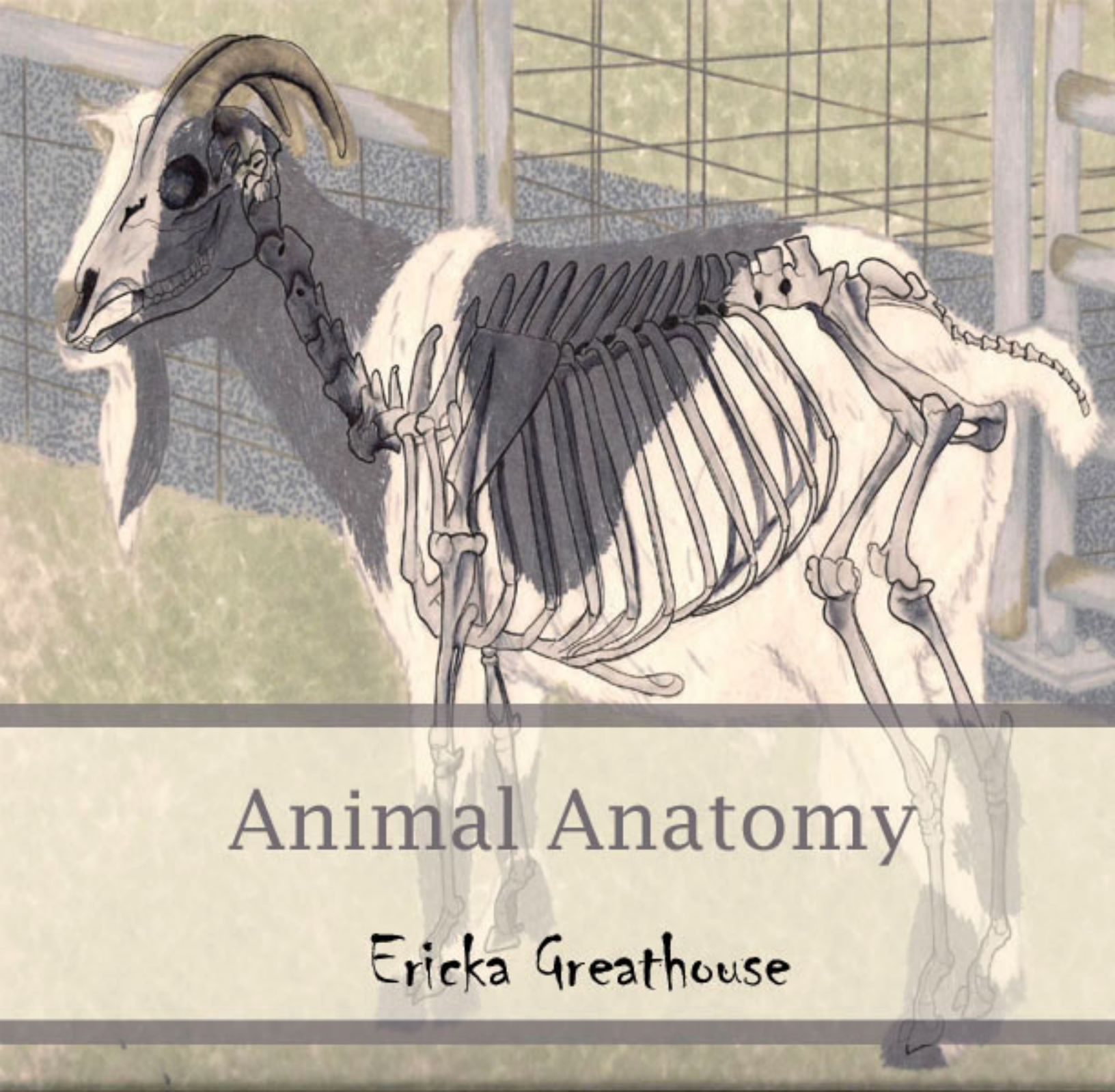

Animal Anatomy

Ericka Greathouse

First Edition, 2012

ISBN 978-81-323-3124-7

© All rights reserved.

Published by:
Research World
4735/22 Prakashdeep Bldg,
Ansari Road, Darya Ganj,
Delhi - 110002
Email: info@wtbooks.com

Table of Contents

Chapter 1 - Anatomical Terms of Location

Chapter 2 - Barbel (Anatomy) and Carapace

Chapter 3 - Exoskeleton

Chapter 4 - Cat Anatomy

Chapter 5 - Horn (Anatomy)

Chapter 6 - Metamorphosis

Chapter 7 - Dog Anatomy

Chapter 8 - Equine Anatomy

Chapter 9 - Suture (Anatomy)

Chapter 10 - Scale (Anatomy)

Chapter- 1

Anatomical Terms of Location

Standard anatomical terms of location are employed in science which deal with the anatomy of animals to avoid ambiguities which might otherwise arise. They are not language-specific, and thus require no translation. They are universal terms that may be readily understood by zoologists who speak any language.

Unfortunately, while these terms are standardized within specific fields of biology, they can differ dramatically from one discipline to another. Differences in terminology remain a problem that, to some extent, still separates the fields of zoological anatomy (sometimes called zootomy) and human (medical) anatomy (sometimes called androtomy).

The Craniata (vertebrates) share a substantial heritage of common structure, allowing much of the same terminology to be used for all of them. It is necessary for this terminology to be based on the anatomy of the animal in a standard way to avoid ambiguities such as might occur if a word such as "top" were used, which might designate the head of a human but the left or right side of a flounder. Most animals, furthermore, are capable of moving relative to their environment. So while "up" might refer to the direction of a standing human's head, the same term ("up") might be thought to point the direction to the belly for a supine human (at least, a sufficiently stout one). It is also necessary to employ some specific anatomical knowledge in order to apply the terminology unambiguously: *E.g.* while the ears would be *superior* to (above) the shoulders in a human, this fails when describing the armadillo, where the shoulders are above the ears. Thus in veterinary terminology, the ears would be *cranial* to (*i.e.* "towards the head from") the shoulders in the armadillo, the dog, the kangaroo, or any other vertebrate, including the human. Similarly, while the belly is considered *anterior* to (in front of) the back in humans, this terminology fails for the flounder, the armadillo and the dog (although it could work for the kangaroo). In veterinary terms, the belly would be *ventral* ("towards the abdomen") in all vertebrates. In human anatomy, as will be explained below, all naming is based on positions relative to the body in a standing (standard anatomical) position with arms at the side and palms facing forwards (thumbs out). While the universal vertebrate terminology used in veterinary medicine would work in human medicine, the human terms are thought to be too well established to change.

For invertebrates, locational terminology becomes more complicated, as many species are not bilaterally symmetrical. In these species, terminology depends on the type of symmetry present (if any).

Thus, standardized anatomical (and zootomical) terms of location have been developed, usually based on Latin words, to enable all biological and medical scientists to precisely delineate and communicate information about animal (including human) bodies and their component organs.

Standard anatomical position

Because animals can change orientation with respect to their environment, and because any appendages (arms, legs, tentacles, *etc.*) can change position with respect to the main body, it is important that any positional descriptive terms refer to the organism when it is in its **standard anatomical position**.

Thus, and very importantly, *all descriptions are with respect to the organism in its standard anatomical position*, even when the organism in question has appendages in another position. For example, see Fig. 9, where the tentacles are curved, and therefore not in anatomical position. However, a straight position is assumed when describing the proximo-distal axis. This helps avoid confusion in terminology when referring to the same organism in different postures.

Medical (human) anatomy

Unlike the situation in zootomy, standard anatomical position is rigidly defined for human anatomy. As with other vertebrates, the human body is standing erect and at rest. Unlike the situation in other vertebrates, the limbs are placed in positions reminiscent of the supine position imposed on cadavers during autopsy. Therefore, the body has its feet together (or slightly separated), and its arms are rotated outward so that the palms are forward, and the thumbs are pointed away from the body (forearms supine). As well, the arms are usually moved slightly out from the body, so that the hands do not touch the sides. The positions of the limbs (and the arms in particular) have important implications for directional terms in those appendages. The penis in males is also erect in the anatomical position, hence the dorsal surface of the penis is actually anterior in the flaccid state.

Skull

In humans, the anatomical position of the skull has been agreed by international convention to be the Frankfurt plane, a position in which the lower margins of the orbits, the orbitales, and the upper margins of the ear canals, the poria, all lie in the same horizontal plane. This is a good approximation to the position in which the skull would be if the subject were standing upright and facing forward normally.

Directional terms

Ultimately, the bodies we are most familiar with are vertebrate bodies similar to our own. All vertebrates (including humans) have the same basic body plan (or bauplan)—they are bilaterally symmetrical. That is, they have mirror-image left and right halves if divided down the centre. For these reasons, the basic directional terms can be considered to be those used in vertebrates. By extension, the same terms are used for many other (invertebrate) organisms as well.

Vertebrate directional terms

To begin, distinct, polar-opposite ends of the organism are chosen. By definition, each pair of opposite points defines an **axis**. In a bilaterally-symmetrical organism, there are 6 polar opposite points, giving three axes that intersect at right angles—the x, y, and z axes familiar from three-dimensional geometry.

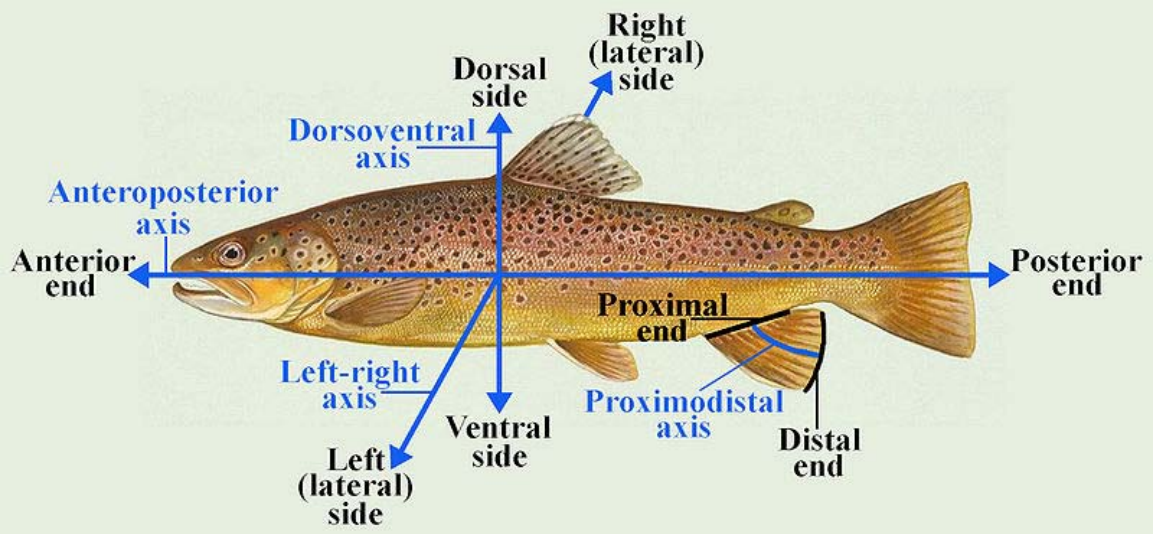

Figure 2: Anatomical directions and defined axes in a vertebrate

Anterior and posterior

The most obvious end-points are the "nose" and "tail" (see Fig. 2). Anatomically, the nose is referred to as the **anterior end** (Latin *ante*; before). In organisms like vertebrates, that have distinct heads, the anterior end is sometimes referred to as the **rostral end** (Latin *rostrum*; beak), the **cranial end** (Greek *kranion*; skull), or the **cephalic end** (Greek *kephalē*; head). For reasons of broader applicability, especially in organisms without distinct heads (many invertebrates), "anterior" is usually preferred.

The polar opposite to the anterior end is the **posterior end** (Latin *post*; after). Another term for posterior is **caudal** (Latin *caudum*; tail, though in humans this refers to the feet i.e. inferior rather than posterior)—a term which strictly applies only to vertebrates, and therefore less preferred, except in veterinary medicine where these terms are standard.

By drawing a line connecting these two points, we define the **anteroposterior axis** (sometimes written antero-posterior). Caudal and Posterior (back end) are often used interchangeably. In veterinary medicine, caudo-cranial is preferred between head and tail, and rostro-caudal between nose and neck. Less-used synonyms would be rostrocaudal or cephalocaudal axes (see Table 1). For brevity, the term anteroposterior is often abbreviated to read **AP** (or A-P) **axis**. As well as defining the anteroposterior axis, the terms "anterior" and "posterior" also define **relative positions** along the axis. Thus, in the fish in Fig. 2, the gill openings are *posterior* relative *to* the eyes, but *anterior to* the tail.

Table 1: Defined Axes in Vertebrate Zoology

Directional term	Defined Axis	Synonyms	Axis runs...
Anterior Posterior	Anteroposterior	Rostrocaudal[1], Craniocaudal[1], Cephalocaudal[2]	...from head end to opposite end of body or tail.
Dorsal Ventral	Dorsoventral	—	...from spinal column (back) to belly (front).
Left (lateral) Right (lateral)	Left-right	Dextro-sinister[2], Sinistro-dexter[2]	...from left to right sides of body.
Medial Left or right (lateral)	Mediolateral[3]	—	...from centre of organism to one or other side.
Proximal Distal	Proximodistal	—	...from tip of an appendage (distal) to where it joins the body (proximal).

Notes:
(1) Fairly common usage.
(2) Uncommon usage.
(3) Equivalent to one-half of the left-right axis.
(The terms "intermediate", "ipsilateral", "contralateral", "superficial" and "deep", while indicating directions, are relative terms and thus do not properly define fixed anatomical axes. Also, while the "rostrocaudal" and anteroposterior directionality are equivalent in a significant portion of the human body, they are different directions in other parts of the body.)

Dorsal and ventral

The next most obvious end-points are the back and belly. These are termed the **dorsal end** (Latin *dorsum*; back) and the **ventral end** (Latin *venter*; abdomen), respectively. By connecting the outermost points the **dorsoventral axis** is formed (sometimes hyphenated: **dorso-ventral**). This is commonly abbreviated to **DV** (or D-V) **axis**. The DV axis, by definition, is perpendicular (at right angles to) the AP axis at all times (see below).

As with anteroposterior, the terms "dorsal" and "ventral" are also used to describe relative positions along the dorsoventral axis. Thus, the pectoral fins are *dorsal to* the anal fin, but *ventral to* the dorsal fin in Fig. 2. (Note that these fins are not aligned anteroposteriorly, either—the dorsal fin being posterior to the pectoral, and anterior to the anal fins, respectively.)

Left and right (lateral), and medial

The last axis, by geometric definition, must be at right angles to both the AP and DV axes. Obviously, the **left side** and **right side** of the organism are the outermost points between the two "sides" of the organism. When connected, these points form the **left-right axis** (commonly abbreviated to **LR** (or L-R) **axis**. In Latin, this is called the **dextro-sinistral** (or, more uncommonly, the **sinistro-dextral**) **axis**, from ***dexter*** (right) and ***sinister*** (left). **It is important to note that the "left" and "right" sides are the sides of *the organism*, and not those of *the observer*.**

"Left-right" is typically used in English and some other languages.

As with the other directions, the terms can be used as relative terms, to describe locations along the left-right axis. Thus, in Fig. 2 the dorsal fin is *right of* the left pectoral fin, but is *left of* the right eye. However, as left and right sides are mirror images, usage like this tends to be somewhat confusing, as structures are duplicated on both sides (*i.e.* above there is both a right eye and a left eye, forcing one to specify which is used as a reference).

To counter this clumsiness of usage, the directional term **lateral** (Latin *lateralis*; "to the side") is used as a modifier for both sides, yielding the **left lateral** and **right lateral** sides. As an opposite to lateral, the term **median** (Latin *medius*; "middle") is used to define a point in the centre of the organism (where the left-right axis intersects the midsagittal plane), and the term **medial** means "towards the median plane". Thus, rather than "left-right" axis and its inherent clumsiness of usage, the term **mediolateral** (also sometimes hyphenated **medio-lateral**) **axis** is frequently used. Sometimes this is abbreviated to **ML** (or M-L) **axis**. Properly, the ML axis is a half axis; practically, its usage is less clumsy and less linguistically biased than "left-right". The terms may still be used relatively to describe locations along the LR axis. Thus, in Fig. 2 the gills are *medial to* the operculum, but *lateral to* the heart.

The usage "mediolateral" is strictly used to describe relative position along the left-right axis, to avoid confusion with the terms "superficial" and "deep".

Sources of confusion

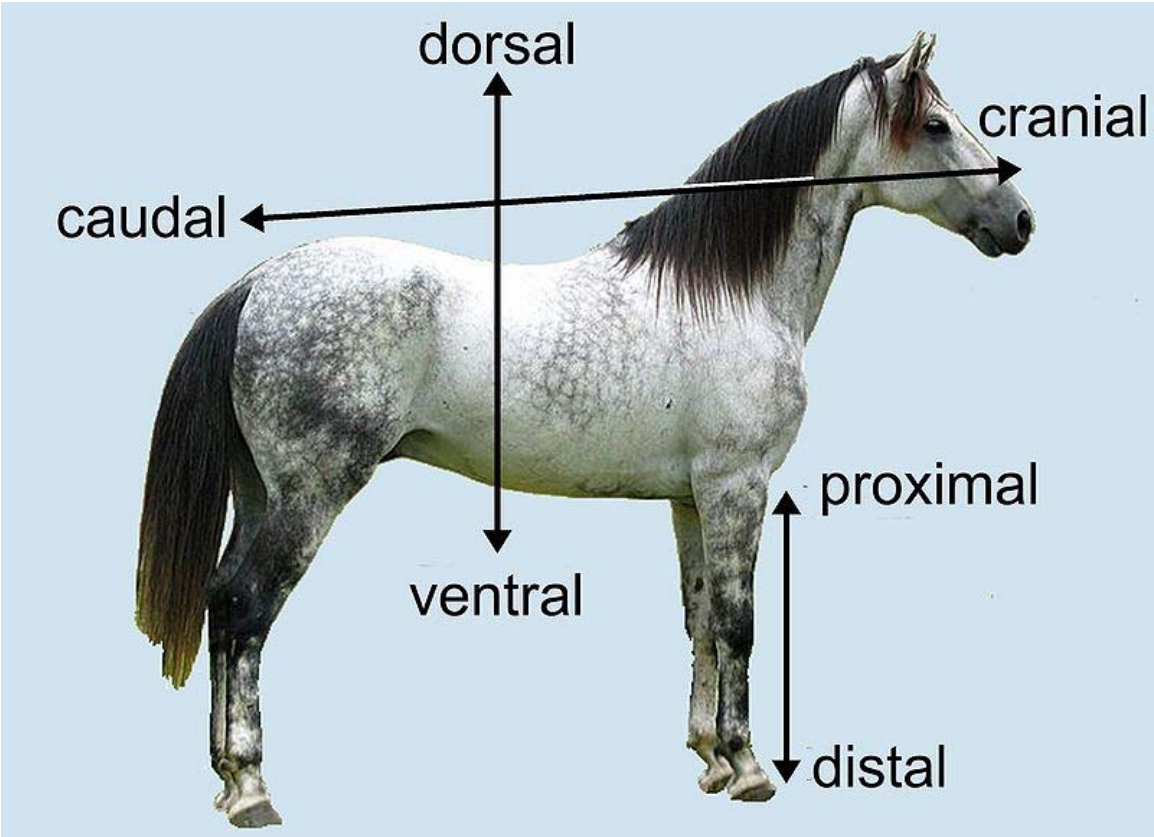

Figure 3: Directional axes in the tetrapod vertebrate *Equus caballus* (a horse). The axis between cranial and caudal is the Cr-Cd axis, and between the dorsal and ventral is the D-V axis. (Left-right axis not shown; image shows the right side of the organism.)

Together, the AP, DV and LR (or ML) axes allow for precise three-dimensional descriptions of location within any bilaterally-symmetrical organism, whether vertebrate or invertebrate. In practice, the terms can cause some confusion when, unlike the fish shown in Fig. 2, the organism in question is not strictly linear in form, which includes most tetrapods (see Figs. 3 and 4). For example, the AP axis in Fig. 3 does not appear to be at right angles to the DV axis. Rather, it is a depiction of the approximate average AP axis, when all body segments are included.

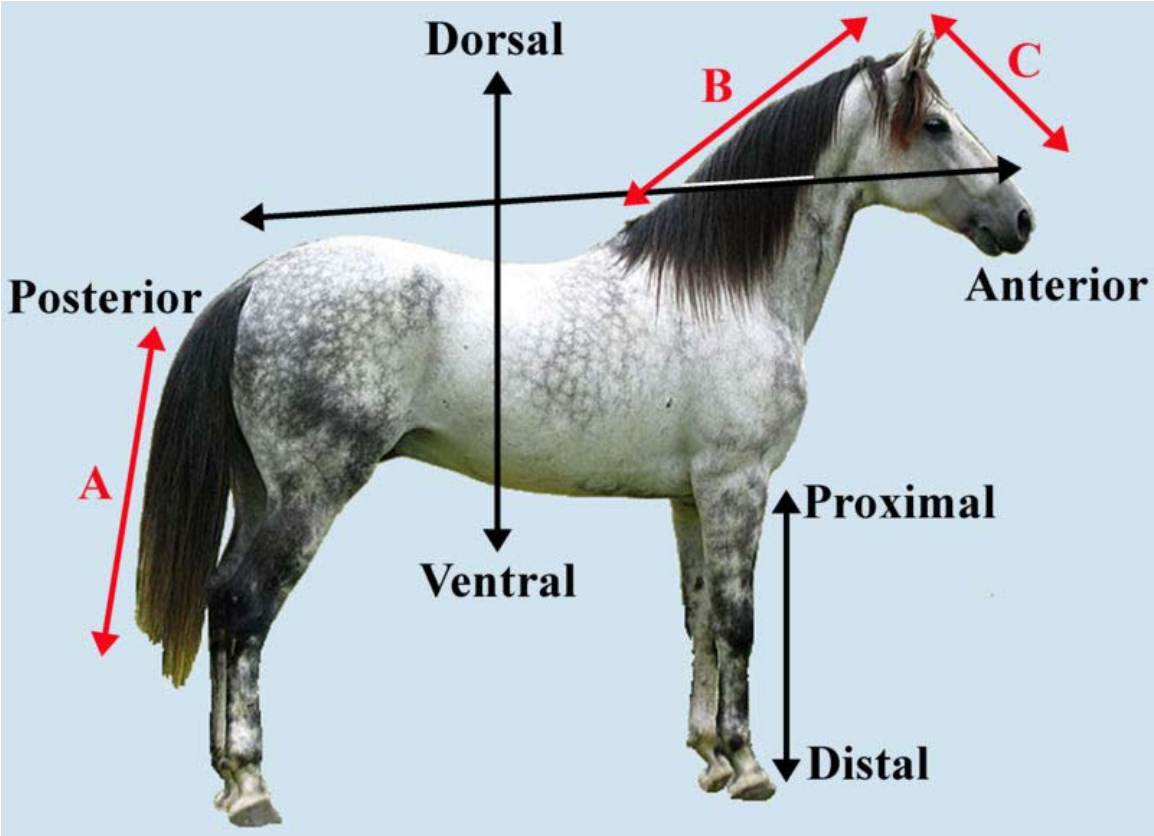

Figure 4: Different directional AP axes in three body segments of a horse). Axis (A) (in red) shows the AP axis of the tail, (B) shows the AP axis of the neck, and (C) shows the AP axis of the head.

When considering *any one segment*, the dorsoventral axis is perpendicular to the AP axis. Thus, in Fig. 4, the DV axis of the tail would run from the "back" of the tail (posterior end of the trunk), to the "underside" of the tail (near the legs)—nearly parallel to the AP axis of the main body.

As a general rule of thumb, if the body is included in consideration, the AP axis of the main body would be used, as would the DV and ML axes perpendicular to it. However, if considering *only* one segment, the AP axis would shift to reflect the axes shown in Fig. 4, with the DV and ML axes shifting correspondingly. Alternatively, to avoid confusion, AP, DV and ML terms are used *strictly* in relation to the main body, and the terms proximal and distal are used for body segments such as the head, neck and tail.

To avoid this confusion, in veterinary medicine, the terms anterior, posterior, superior, and inferior are generally avoided except for certain structures within the head. By using the terms cranial, caudal, dorsal and ventral, all tetrapod organisms (including bipeds) can be described uniformly.

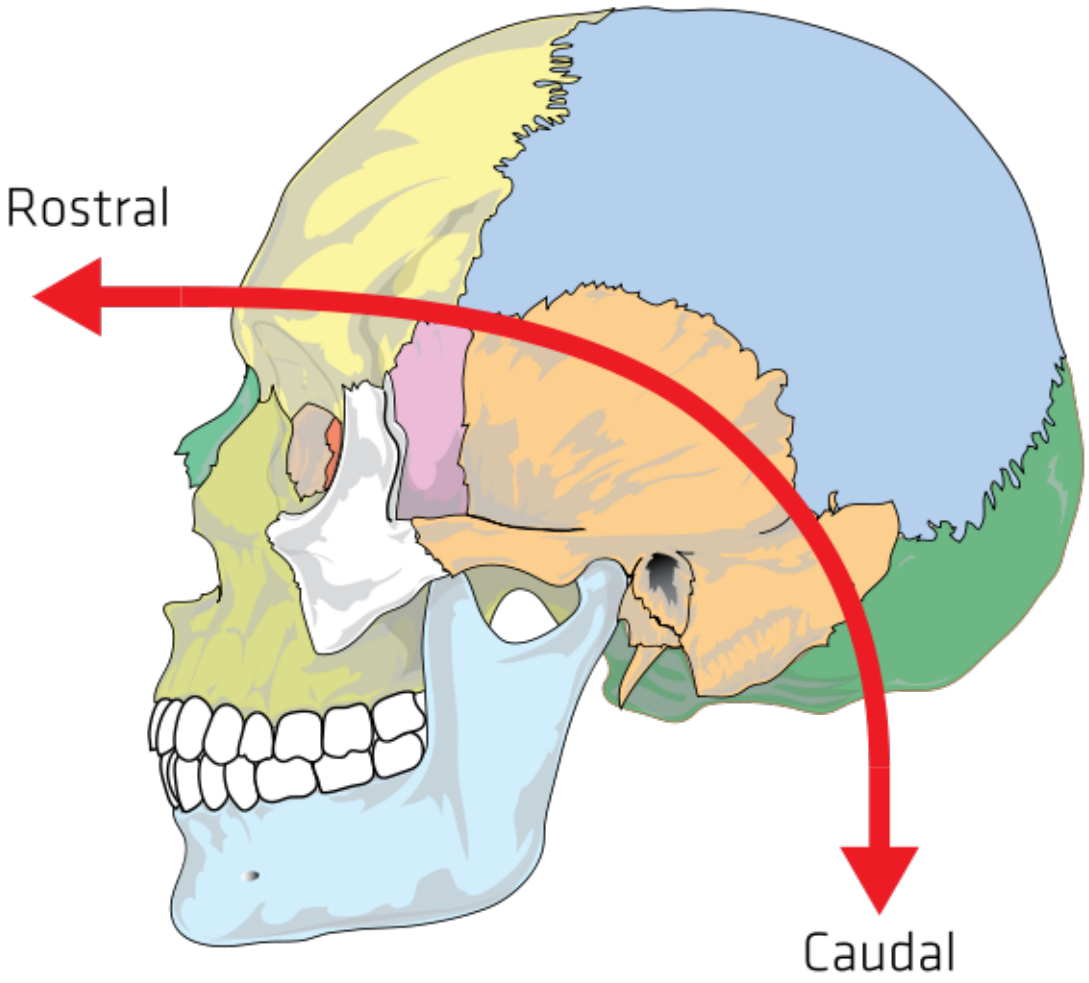

Rostral and Caudal shown on a human skull

In humans, the directions "rostral" and "caudal" often become confused with anterior and posterior, or superior and inferior. The difference between the two is most easily visualized when looking at the head, as can be seen in the image to the right. From the most caudal of positions in the nervous system (of a person) to a nearby, rostral area, it is equally accurate to say the area in question is rostral as to say it is superior. However, in the frontal lobes of the telencephalon, to say an area is rostral to a nearby area is equivalent to saying it is anterior (or ventral). Those two lines lie on planes perpendicular to one another! This occurs, as becomes clear in the diagram, due to the intuitive yet curious curving "C" shape of rostrocaudal directionality when discussing the human brain.

Proximal and distal

The term **proximal** (Latin *proximus*; nearest; aka. "proxil") describes where the appendage joins the body, and the term **distal** (Latin *distare*; to stand away from) is used for the point furthest from the point of attachment to the body. Since appendages often move independently of (and therefore change position with respect to) the main body, these separate directional terms are used when describing them.

As noted above, the standard AP, DV and ML directional axes, can cause some confusion when describing parts of the body that can change position (move) relative to the main body. This is particularly true when considering **appendages**. "Appendages" would include vertebrate fins (see Fig. 2) and limbs (see Figs. 3 and 4), but properly apply to any structure that extends (and can at least potentially move separately) from the main body. Thus, "appendage" would also include such structures as external ears (pinnae) and hair (in mammals), feathers (in birds) and scales (fish, reptiles and birds). As well, varieties of tentacles or other projections from the body in invertebrates and the male in many vertebrates and some invertebrates, would be included.

By connecting the two points, the **proximodistal** (sometimes hyphenated to **proximo-distal**) **axis** is created. (The abbreviation **AB axis** is occasionally, but not commonly, used.) As before, the terms "proximal" and "distal" can be used as relative terms to indicate where structures lie along the proximodistal axis. Thus, the "elbow" is proximal to the hoof, but distal to the "shoulder" in Figs. 3 and 4.

Choosing terms for the other two axes perpendicular to the proximodistal axis could be variable, as they would also depend on the position of the limb. For that reason, when considering any organism, the other two axes are considered to be relative to the appendage **when in standard anatomical position**. This is roughly defined for all organisms, as in the normal position when at rest and not moving. For tetrapod vertebrates, this includes the caveat that they are standing erect and not lying down. Thus, the fish in Fig. 2, and the horse in Figs. 3 and 4 are in standard anatomical position. (Special considerations with respect to limb position are applied in human anatomy).

Other directional terms

In addition to the three primary axes (AP, DV and the ML half-axis) and the proximodistal axis of appendages, several directional terms can be used in bilaterally symmetrical animals. These terms are **strictly relative**, and as such *do not and cannot be used to define fixed axes*. These terms include:

- **Ipsilateral** (Latin *ipse*; self/same): on the same side as another structure. Thus, the left arm is **ipsilateral to** the left leg.
- **Contralateral** (Latin *contra*; against): on the opposite from another structure. Thus, the left arm is **contralateral to** the right arm, or the right leg.

- **Superficial** (Latin *superfacies; at the surface or face*): near the outer surface of the organism. Thus, skin is **superficial to** the muscle layer. The opposite is "deep", or "visceral".
- **Deep**: further away from the surface of the organism. Thus, the muscular layer is **deep to** the skin, but superficial to the intestines. This is one of the few terms where the English vernacular is prevalent. The proper anglicised Latin term would be **profound** (Latin *profundus*; due to depth), but this word has other meanings in English. In other languages, the equivalent term is usually similar to "profound" (*e.g. profond*, meaning deep, in French).
- **Intermediate** (Latin *intermedius*; *inter*, between and *medius*, middle): between two other structures. Thus, the navel is **intermediate to** (or **intermediate between**) the left arm and the contralateral (right) leg.
- **Visceral** (Latin *viscus*; *internal organs*, *flesh*): associated with organs within the body's cavities. The stomach is a viscus within the abdominal cavity, and is covered with a lining called the visceral peritoneum.
- **Parietal** (Latin *paries* "wall"): pertaining to the wall of a body cavity. The parietal peritoneum is the lining on the inside of the abdominal cavity. (Parietal can also refer specifically to the parietal bone of the skull or associated structures.)
- **Axial** (Latin *axis* from Greek *axōn* "axle"): Towards the central axis of the organism or an extremity.
- **Abaxial** : away from the central axis of the organism or extremity
- **Rostral** (Latin - rostr(um), *beak* or *nose*): situated toward the oral or nasal region, or in the case of the brain, towards the tip of the frontal lobes.
- **Caudal** (Latin - caud(a), *tail*): of, at, or near the tail or the posterior end of the body. In the human case, towards the bottom of the feet (also the "tail" of the spinal cord, and body).

Invertebrate directional terms

The large variety of body shapes present in invertebrates presents a difficult problem when attempting to apply standard directional terms. Depending on the organism, some terms are taken by analogy from the vertebrate terms, and appropriate novel terms are applied, as necessary. In all cases, the usage of terms is dependent on the bauplan of the organism.

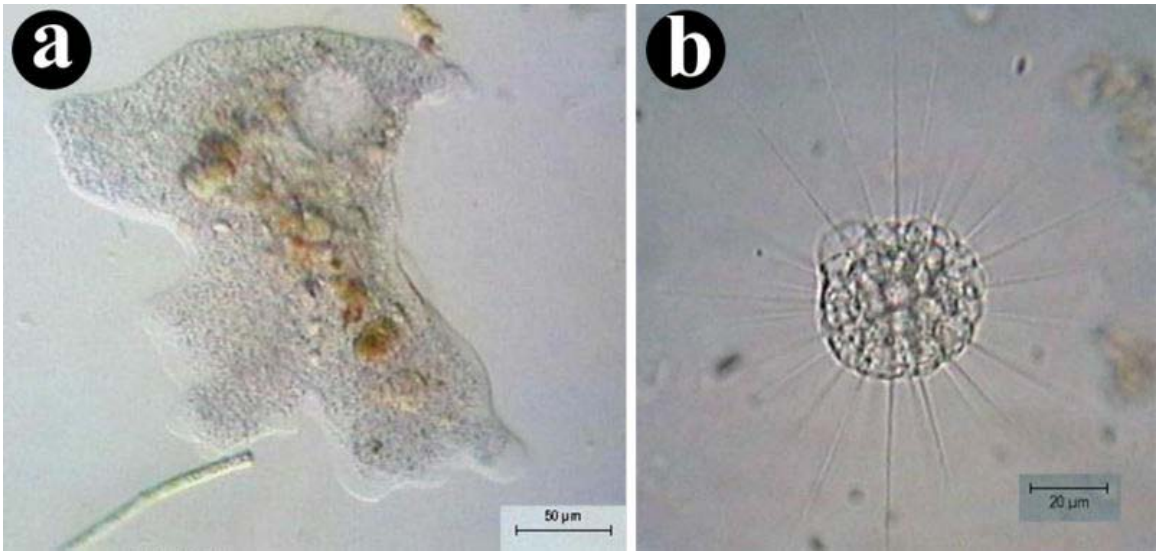

Figure 5: Asymmetrical and spherical body shapes. (a) An organism with an asymmetrical bauplan (*Amoeba proteus*—an amoeba). (b) An organism with a spherical bauplan (*Actinophrys sol*—a heliozoan.

Asymmetrical and spherical organisms

In organisms with a changeable shape, such as amoeboid organisms (Fig. 5a), directional terms are meaningless, since the shape of the organism is changeable, and no fixed axes are present. Similarly, in organisms that are spherical in shape (Fig. 5b), there is nothing to distinguish one line through the centre of the organism from another. An infinite number of triads of mutually perpendicular axes could be defined, but any such choice of axes would be functionally and practically indistinguishable from all others, and therefore would be useless. In such organisms, only the terms *superficial* and *deep* hold any descriptive meaning.

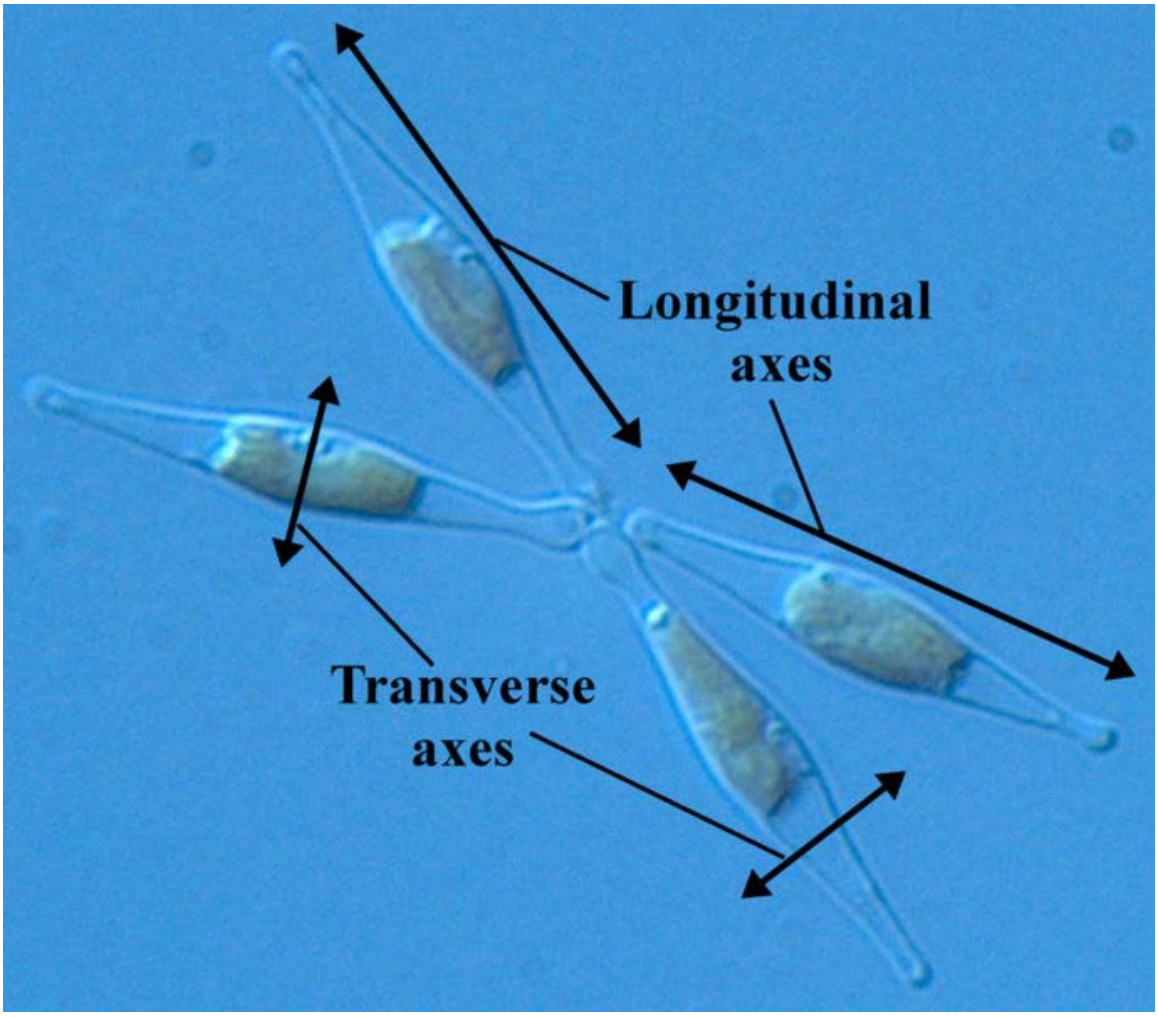

Figure 6: Four individuals of *Phaeodactylum tricornutum*, a diatom with a fixed elongated shape.

Elongated organisms

In organisms that maintain a constant shape and have one dimension longer than the other, at least two directional terms can be used. The **long** or **longitudinal axis** is defined by points at the opposite ends of the organism. Similarly, a perpendicular **transverse axis** can be defined by points on opposite sides of the organism. There is typically no basis for the definition of a third axis. Usually such organisms, like that pictured in Fig. 6, are planktonic (free-swimming) protists, and are nearly always viewed on microscope slides, where they appear essentially two-dimensional. In some cases a third axis can be defined, particularly where a non-terminal cytostome or other unique structure is present.

Elongated organisms with distinctive ends

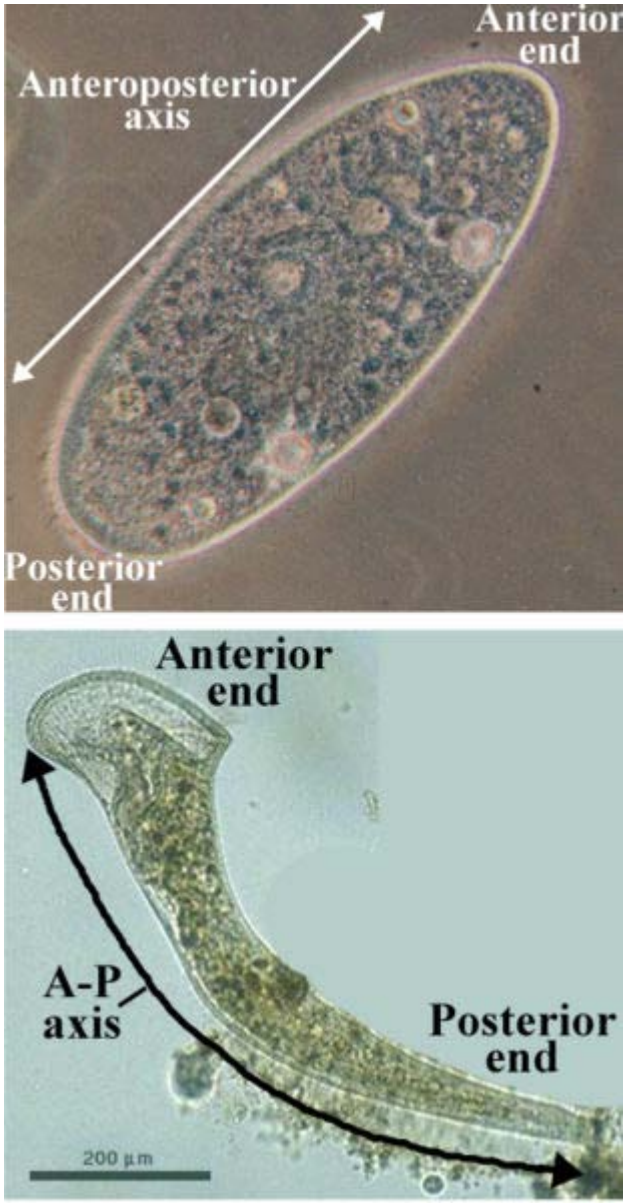

Figure 7: Organisms where the ends of the long axis are distinct. (*Paramecium caudatum*, above, and *Stentor roeseli*, below.)

Some elongated protists have distinctive ends of the body. In such organisms, the end with a mouth (or equivalent structure, such as the cytostome in *Paramecium* or *Stentor*), or the end that usually points in the direction of the organism's locomotion (such as the end with the flagellum in *Euglena*), is normally designated as the **anterior end**. The opposite end then becomes the **posterior end**, and by connecting them, an **anteroposterior axis** is formed. Properly, this terminology would only apply to an organism that is always planktonic (not normally attached to a surface, as in Fig. 7 top), although the term can also be applied to one that is sessile (normally attached to a surface, as in Fig. 7, bottom, and Fig. 8).

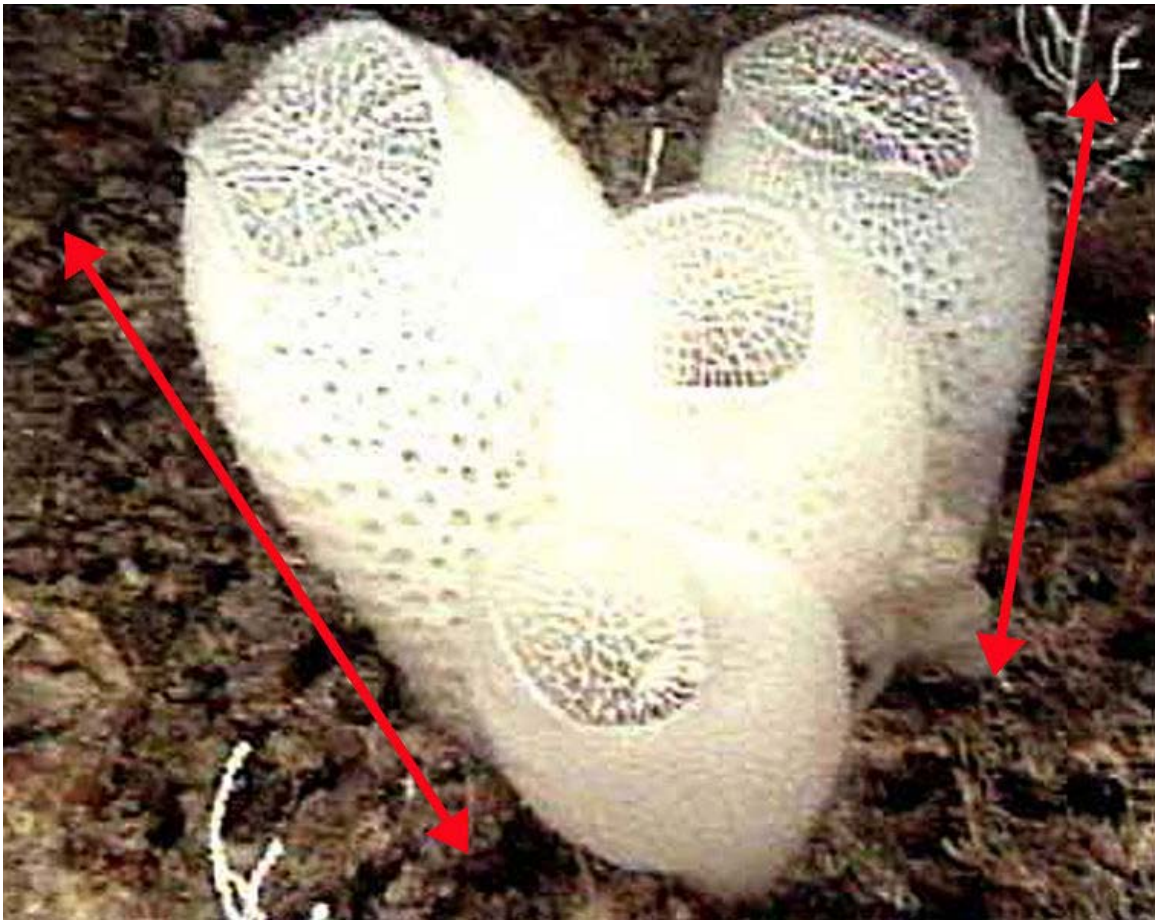

Figure 8: A cluster of *Euplectella aspergillum* sponges (Venus flower baskets), showing the apical-basal axes.

Organisms that are attached to a substrate, such as sponges (Fig. 8), or some animal-like protists also have distinctive ends. The part of the organism attached to the substrate is usually referred to as the **basal end** (Latin *basis*; support or foundation), whereas the end furthest from the attachment is referred to as the **apical end** (Latin *apex*; peak, tip). Thus, by joining the two ends, an **apical-basal** (or **basal-apical**) **axis** is formed (see Fig. 8). **Transverse axes** may be defined indifferently in any direction perpendicular to this axis, as there is no symmetry present.

Radially-symmetrical organisms

Radially symmetrical organisms include those in the group Radiata—primarily jellyfish, sea anemones and corals and the comb jellies. Adult echinoderms (sea stars (starfish), sea urchins, and sea cucumbers and others) are also included, since they are pentaradial (*i.e.* they have fivefold discrete rotational symmetry). Echinoderm larvae are *not* included, since they are bilaterally symmetrical.

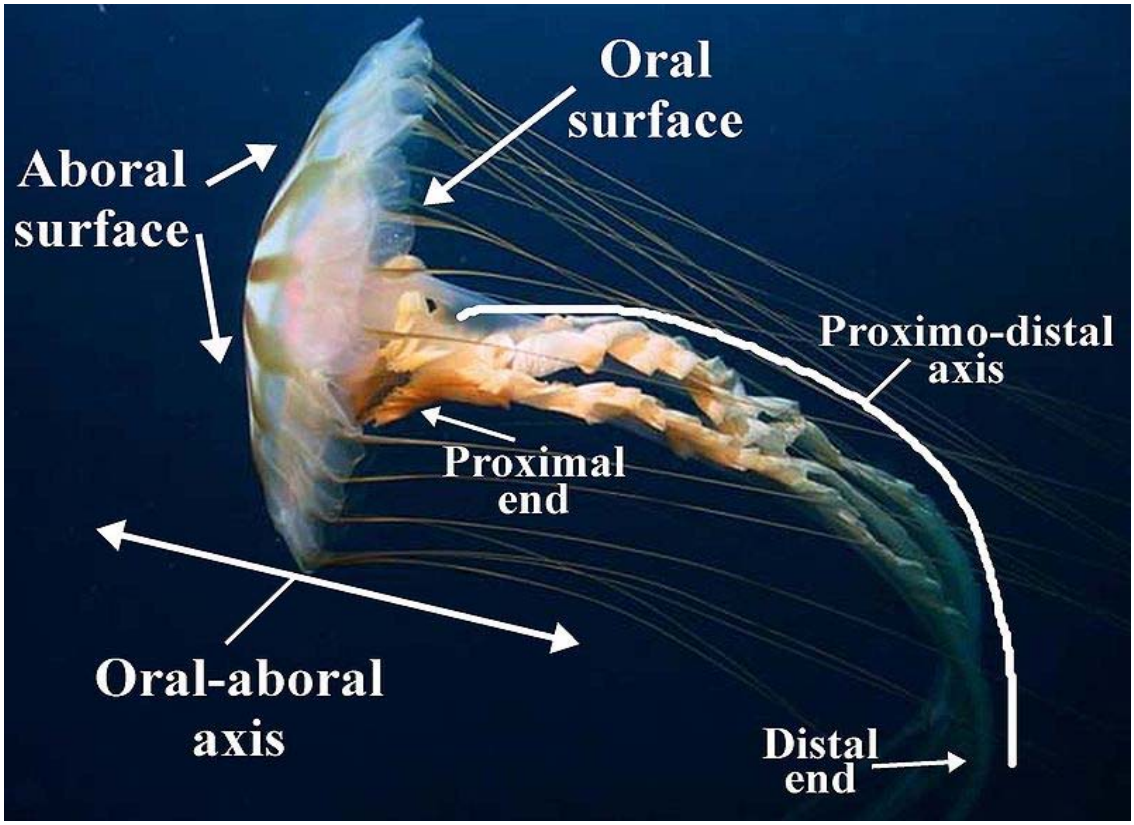

Figure 9: *Chrysoara spp.* (a jellyfish), showing the oral-aboral, and proximodistal axes. (Note that the appendages are not in standard anatomical position, so that the axis is curved.)

Unlike spherical and asymmetrical organisms, radially-symmetrical animals always have one distinctive axis.

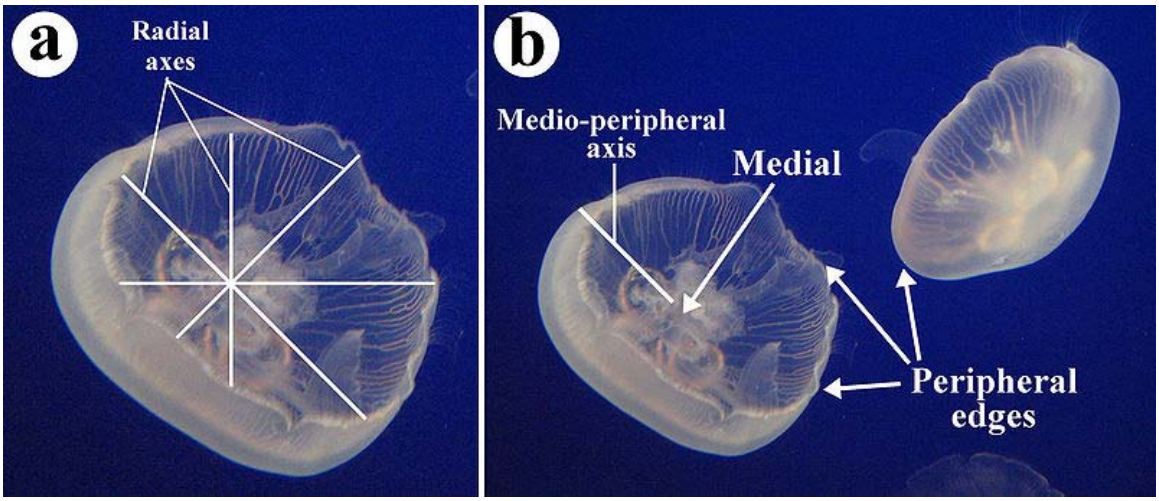

Figure 10: *Aurelia aurita*, another species of jellyfish, showing multiple radial and medio-peripheral axes.

Cnidarians have an incomplete digestive system, meaning that one end of the organism has a mouth, and the opposite end has no opening from the gut (coelenteron). For this reason, the end of the organism with the mouth is referred to as the **oral end** (Latin *oris*; mouth), and the opposite surface is the **aboral end** (Latin *ab*-; prefix meaning "away from"). Thus, by joining the polar opposite oral and aboral ends, an **oral-aboral axis** is formed (Fig. 9).

As with vertebrates, appendages that move independently of the body (tentacles in cnidarians and comb jellies), have a definite **proximodistal axis** (Fig. 8). Unlike vertebrates, cnidarians (jellyfish, sea anemones, corals) have no other distinctive axes, and multiple **radial axes** are possible (Fig. 10).

It is noteworthy that some "biradially-symmetrical" comb jellies have distinct "**tentacular**" and "**pharyngeal**" axes, and are thus anatomically equivalent to bilaterally-symmetrical animals. As well, adult echinoderms (starfish, sea urchins, sea cucumbers) are *pentaradial*, and have only five symmetrical radial axes (unlike the multiple axes in cnidarians).

Lateral, **dorsal**, and **ventral** have no meaning in such organisms, and all can be replaced by the generic term **peripheral** (Latin *peri*-; around; see Table 2). **Medial** can be used, but in the case of radiates indicates the central *point* of these organisms, rather than a central *axis* (as in vertebrates). Thus, as there are many possible radial axes, there are multiple **medio-peripheral** (half-) **axes** (Fig. 10).

Table 2: Comparison of Directional Terms used in Radially-Symmetrical[1] and Bilaterally-Symmetrical Animals

Bilateral Bauplans		Radial Bauplans	
Direction	**Synonyms**	**Direction**	**Synonyms**
Anterior	Rostral, Cranial, Cephalic[2]	Oral	Apical[3]
Posterior	Caudal[2]	Aboral	Basal[3]
Dorsal	—	Peripheral[4,5]	—
Ventral	—	Peripheral[4,5]	—
Left (lateral)	Sinister	Peripheral[4,5]	—
Right (lateral)	Dexter	Peripheral[4,5]	—
Medial	—	*Same*[6]	—
Proximal	—	*Same*	—
Distal	—	*Same*	—

Notes:
(1) Includes both Radiates and adult Echinoderms.
(2) Rarely used.
(3) Only in organisms attached to a substrate.
(4) Vertebrate equivalents are meaningless in radial animals.
(5) Roughly equivalent to "superficial".
(6) Roughly equivalent to "deep".

Arachnids

Two specialized terms are sometimes used for describing views of arachnid legs and pedipalps. **Prolateral** refers to the surface of a leg which is closest to the anterior end of an arachnid's body. **Retrolateral** refers to the surface of a leg which is closest to the posterior end of an arachnid's body.

Medical (human) directional terms

As humans are bilaterally-symmetrical organisms, anatomical directions in humans can usually be correctly described using the same terms as those for vertebrates and other members of the taxonomic group Bilateria. However, for historical and other reasons, standard human directional terminology has several differences from that used for other bilaterally-symmetrical organisms.

Why zootomy and androtomy terms differ

The terms of zootomy and androtomy came into usage at a time when all scientific communication took place in Latin. In their original Latin forms the respective meanings of "anterior" and "posterior" are *in front of* (or *before*) and *behind* (or *after*), those of "dorsal" and "ventral" are *towards the spine* and *towards the belly*, and those of "superior" and "inferior" are *above* and *below*. From these meanings it can be seen that in the most general terms the anterior/posterior axis is oriented to the direction of forward motion, the dorsal/ventral axis is oriented to the anatomy of the vertebrate torso, and the superior/inferior axis is oriented to gravity.

For almost all vertebrates, including almost all bipeds, these axes all provide a consistent reference for anatomical positions across species—with the inferior/superior axis being roughly the same as the dorsal/ventral axis, and therefore redundant. Humans, however, have the rare property of having a torso oriented perpendicular to their direction of forward motion—while their head orientation remains consistent with other vertebrates on this axis. This makes the dorsal/ventral axis on humans redundant with the anterior/posterior axis, and the inferior/superior axis necessary. Because of this difference with humans, the anterior/posterior and inferior/superior axes are inconsistent between humans and other vertebrates in torso anatomy but consistent in head anatomy. As all three of these axes are used in the naming of anatomical structures, and most human anatomical structures are shared by other animals, these differences can lead to considerable confusion. For example, in the naming of brain structures, the non-human context of the dorsal/ventral axis was used. Therefore, in human anatomy, "dorsal" can refer to two different (perpendicular) directions—the posterior direction in the context of the torso, and the superior direction in the context of the brain. Ironically, the "dorsal" direction in the human brain, besides being perpendicular to the "dorsal" direction in the human torso, is actually the *opposite* direction of what might be inferred from the literal Latin meaning of "toward the spine".

While it would be possible to introduce a system of axes that is completely consistent between humans and other vertebrates by having two separate pairs of axes, one used exclusively for the head (e.g. anterior/posterior and inferior/superior) and the other exclusively for the torso (e.g. dorsal/ventral and caudal("toward the tail")/rostral("toward the beak")), doing so would require the renaming very many anatomical structures.

For a quick comparison of equivalent terminology used in vertebrate and human anatomy, see Table 3 (below).

Table 3: Equivalent directional terms used in vertebrate zoology and human anatomy

Vertebrate zootomy		Human torso		Human head	
Direction	**Synonyms**	**Direction**	**Synonyms**	**Direction**	**Synonyms**
Anterior	Rostral, Cranial, Cephalic[1]	Superior	*Same*[1], Up	Anterior	Front
Posterior	Caudal	Inferior	Caudal[1], Down	Posterior	Back
Dorsal	—	Posterior	Dorsal, Back	Superior	Dorsal, Up
Ventral	—	Anterior	Ventral, Front	Inferior	Ventral, Down
lateral	Away from the middle	*Same*	—	*Same*	—
Left (lateral)	Sinister[1]	*Same*	—	*Same*	—
Right (lateral)	Dexter[1]	*Same*	—	*Same*	—
Medial	Middle	*Same*	—	*Same*	—
Proximal	Away from extremity	*Same*	—	*Same*	—
Distal	Towards extremity	*Same*	—	*Same*	—
Intermediate[2]	—	*Same*	—	*Same*	—
Ipsilateral[2]	Same side	*Same*	—	*Same*	—
Contralateral[2]	Opposite side	*Same*	—	*Same*	—
Superficial[2]	—	*Same*	—	*Same*	—
Deep[2]	—	*Same*	—	*Same*	—

Notes:
(1) Rarely used.
(2) Strictly relative term, used with other locational descriptors.

Superior and inferior

As with other vertebrates, two of the most obvious extremes are the "top" and the "bottom" of the organism. In standard anatomical position, these correspond to the head and feet, respectively in humans. The head end is referred to as the **superior end** (Latin *superior*: "above"), while the feet are referred to as the **inferior end** (Latin *inferior*: "below"). Thus, the axis formed by joining the two is the **superior-inferior axis**.

As with other vertebrate terminology, there are synonymous terms for superior and inferior (Table 3). The terms **cranial** and **cephalic** are often encountered. "Cranial", as a reference to the skull, is fairly commonly used, whereas "cephalic" is uncommonly used. The term "rostral" is rarely used in human anatomy, referring more to the front of the face than the superior aspect of the organism. This term is more applicable in organisms with longer heads, such as equids. Similarly, the term **caudal** is occasionally used in human anatomy, and the **cranio-caudal axis** is occasionally encountered. Generally, this usage would only be used with respect to the head and main body (trunk), and not when considering the limbs.

As with vertebrate directional terms, superior and inferior can be used in a relative sense in humans, but can not be uniformly applied to other organisms with varying normal anatomical positions. For example, the shoulders are *superior to* the navel, but *inferior to* the eyes in humans. In any tetrapod, the shoulders are *cranial to* the belly, but *caudal to* the eyes.

Anterior and posterior

In human anatomical usage, **anterior** refers to the "front" of the individual, and is *synonymous with* ***ventral***, other than in the head. Similarly, **posterior**, refers to the "back" of the subject, and is *synonymous with* ***dorsal***, other than in the head (see Table 3). The terms "dorsal" and "ventral" are used in human anatomy, but infrequently when referring to the body as a whole. The **anteroposterior axis** is preferred usage for describing the axis connecting the front and the back in humans.

"Anterior" and "posterior" can also be used as relative terms. Thus, the eyes are *posterior to* the nose, but *anterior to* the back of the head in humans. However, in the horse, for example, the eyes are *caudal to* the nose, and rostral to the back of the head.

Left and right (lateral), and medial

Left and right **lateral** are used in the same sense as they are in other vertebrates, as is **medial**. The **left-right axis** is rarely used in medicine; instead, the **mediolateral axis** is used almost exclusively.

Appendages

As in other vertebrates, the terms "**proximal**" and "**distal**" are used to describe the point of attachment to, and part of an appendage furthest away from, the body, respectively. However, other terms are used for direction in the appendages, given the unique position of the limbs (in standard anatomical position) in humans.

Relative directions

Also, in common usage, the segments of the digestive system closest to the mouth are termed **proximal**, as opposed to those closest to the anus, which are termed **distal**. The terms *oral* "of the mouth" and *aboral* "away from the mouth" are also used.

Relative directions in the limbs

Specialized terms are used to describe location on appendages, parts that have a point of attachment to the main trunk of the body. Structures that are close to the point of attachment of the body are **proximal** or **central**, while ones more distant from the attachment point are **distal** or **peripheral**. For example, the hands are at the distal end of the arms, while the shoulders are at the proximal ends. These terms can also be used relatively to organs, for example the proximal end of the urethra is attached to the bladder.

In the limbs of most animals, the terms **cranial** and **caudal** are used in the regions proximal to the carpus (the wrist, in the forelimb) and the tarsus (the ankle in the hindlimb). Objects and surfaces closer to or facing towards the head are *cranial*; those facing away or farther from the head are *caudal*.

Distal to the carpal joint, the term **dorsal** replaces **cranial** and **palmar** replaces **caudal**. Similarly, distal to the tarsal joint the term **dorsal** replaces **cranial** and **plantar** replaces **caudal**. For example, the top of a dog's paw is its *dorsal* surface; the underside, either the *palmar* (on the forelimb) or the *plantar* (on the hindlimb) surface.

The sides of the forearm are named after its bones: Structures closer to the radius are **radial**, structures closer to the ulna are **ulnar**, and structures relating to both bones are referred to as **radioulnar**. Similarly, in the lower leg, structures near the tibia (shinbone) are **tibial** and structures near the fibula are **fibular** (or **peroneal**).

Volar (sometimes used as a synonym for "palmar") refers to the underside, for both the palm and the sole (*plantar*), as in **volar pads** on the underside of hands, fingers, feet and toes.

The terms valgus and varus are used to refer to angulation of the distal part of a limb at a joint. For example, at the elbow joint, in the anatomical position, the forearm and the upper arm do not lie in a straight line, but the forearm is angulated laterally with respect to the upper arm by about 5–10°. The forearm is said to be "in valgus". Angulation at a joint may be normal (as in the elbow) or abnormal.

General usage

Three basic reference planes are used in zoological anatomy.

- A **sagittal plane**, being a plane parallel to the sagittal suture, divides the body into sinister and dexter (left and right) portions.
    - The **midsagittal** or **median** plane is in the mid line; i.e. it would pass through mid line structures such as the navel or spine, and all other sagittal planes (also referred to as **parasagittal planes**) are parallel to it. Median can also refer to the midsagittal plane of other structures, such as a digit.
- A **coronal** or **frontal** plane divides the body into dorsal and ventral (back and front, or posterior and anterior) portions.
- A **transverse plane**, also known as an *axial plane* or *cross-section*, divides the body into cranial and caudal (head and tail) portions.

For post-embryonic humans a coronal plane is vertical and a transverse plane is horizontal, but for embryos and quadrupeds a coronal plane is horizontal and a transverse plane is vertical.

When describing anatomical motion, these planes describe the axis along which an action is performed. So by moving through the transverse plane, movement travels from head to toe. For example, if a person jumped directly up and then down, their body would be moving through the transverse plane in the coronal and sagittal planes.

Some of these terms come from Latin. *Sagittal* means "like an arrow", a reference to the position of the spine which naturally divides the body into right and left equal halves, the exact meaning of the term "midsagittal", or to the shape of the sagittal suture, which defines the sagittal plane and is shaped like an arrow.

A *longitudinal plane* is any plane perpendicular to the transverse plane. The coronal plane and the sagittal plane are examples of longitudinal planes.

Usage in human anatomy

Sometimes the orientation of certain planes needs to be distinguished, for instance in medical imaging techniques such as sonography, CT scans, MRI scans, or PET scans. One imagines a human in the anatomical position, and an X-Y-Z coordinate system with the Z-axis going from front to back, the X-axis going from left to right, and the Y-axis going from up to down. The Z-axis axis is always forward (Tait-Bryan angles) and the right-hand rule applies.

- A **transverse** (also known as **axial** or **horizontal**) plane is an X-Z plane, parallel to the ground, which (in humans) separates the superior from the inferior, or put another way, the head from the feet.
- A **coronal** (also known as **frontal**) plane is a Y-X plane, perpendicular to the ground, which (in humans) separates the anterior from the posterior, the front from the back, the ventral from the dorsal.
- A **sagittal** (also known as **lateral**) plane is an Y-Z plane, perpendicular to the ground, which separates left from right. The midsagittal plane is the specific sagittal plane that is exactly in the middle of the body.

The axes and the sagittal plane are the same for bipeds and quadrupeds, but the orientation of the coronal and transverse planes switch. The axes on particular pieces of equipment may or may not correspond to axes of the body, especially since the body and the equipment may be in different relative orientations.

Occasionally, in medicine, abdominal organs may be described with reference to the **trans-pyloric plane** which is a transverse plane passing through the pylorus.

Anatomical planes in animal brains

In discussing the neuroanatomy of animals, particularly rodents used in neuroscience research, a simplistic convention has been to name the sections of the brain according to the homologous human sections. Hence, what is technically a *transverse* (orthogonal) section with respect to the body length axis of a rat (dividing anterior from posterior) may often be referred to in rat neuroanatomical coordinates as a *coronal* section, and likewise a *coronal* section with respect to the body (i.e. dividing ventral from dorsal) in a rat brain is referred to as *transverse*. This preserves the comparison with the human brain, whose length axis in rough approximation is rotated with respect to the body axis by **90 degrees** in the ventral direction. It implies that the planes of the brain are not necessarily the same as those of the body.

Actually, the situation is more complex, since comparative embryology shows that the length axis of the neural tube (the primordium of the brain) has three internal bending points, namely two ventral bendings at the cervical and cephalic flexures (cervical flexure roughly between the medulla oblongata and the spinal cord, and cephalic flexure between the diencephalon and the midbrain), and a dorsal (pontine or rhombic) flexure at the midst of the hindbrain, behind the cerebellum. The latter flexure mainly appears in mammals and sauropsids (reptiles and birds), whereas the other two, and principally the cephalic flexure, appear in all vertebrates (the sum of the cervical and cephalic ventral flexures is the cause of the 90 degree angle mentioned above in humans between body axis and brain axis). This more realistic concept of the longitudinal structure of vertebrate brains implies that any section plane, except the sagittal plane, will intersect variably different parts of the same brain as the section series proceeds across it (relativity of actual sections with regard to topological morphological status in the ideal unbent neural tube). Any precise description of a brain section plane therefore has to make reference to the anteroposterior part of the brain to which the description refers (e.g., transverse to the midbrain, or horizontal to the diencephalon). A necessary note of caution is that modern embryologic orthodoxy indicates that the brain's true length axis finishes rostrally somewhere in the hypothalamus where basal and alar zones interconnect from left to right across the median line; therefore, the axis does not enter the telencephalic area, although various authors, both recent and classic, have assumed a telencephalic end of

the axis. The causal argument for this lies in the end of the axial mesoderm -mainly the notochord, but also the prechordal plate- under the hypothalamus. Early inductive effects of the axial mesoderm upon the overlying neural ectoderm is the mechanism that establishes the length dimension upon the brain primordium, jointly with establishing

what is ventral in the brain (close to the axial mesoderm) in contrast with what is dorsal (distant from the axial mesoderm). Apart of the lack of a causal argument for introducing the axis in the telencephalon, there is the obvious difficulty that there is a pair of telencephalic vesicles, so that a bifid axis is actually implied in these outdated versions.

Chapter- 2

Barbel (Anatomy) and Carapace

Barbel (anatomy)

This koi carp has two pairs of barbels, the second pair being quite small.

This Asian arowana has large, protruding barbels

A **barbel** on a fish is a slender, whiskerlike tactile organ near the mouth. Fish that have barbels include the catfish, the carp, the goatfish, sturgeon, the zebrafish (*Danio rerio*) and some species of shark. They house the taste buds of such fish and are used to search for food in murky water.

Barbels are often erroneously referred to as *barbs*, which are found in bird feathers for flight.

Barbels may be located in a variety of places. Maxillary barbels refer to barbels on either side of the mouth. Barbels may also be nasal, or extended from the nostrils. Also, barbels are often mandibular or mental, or located on the chin.

Barbel are frequently featured in the fishing magazine *Angler's Mail* as well as many other fishing publications.

Carapace

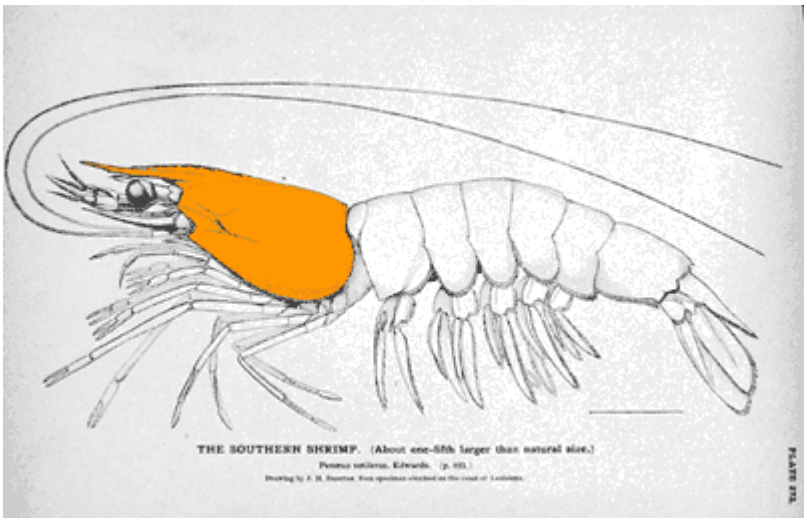

Diagram of a prawn, with the carapace highlighted in orange

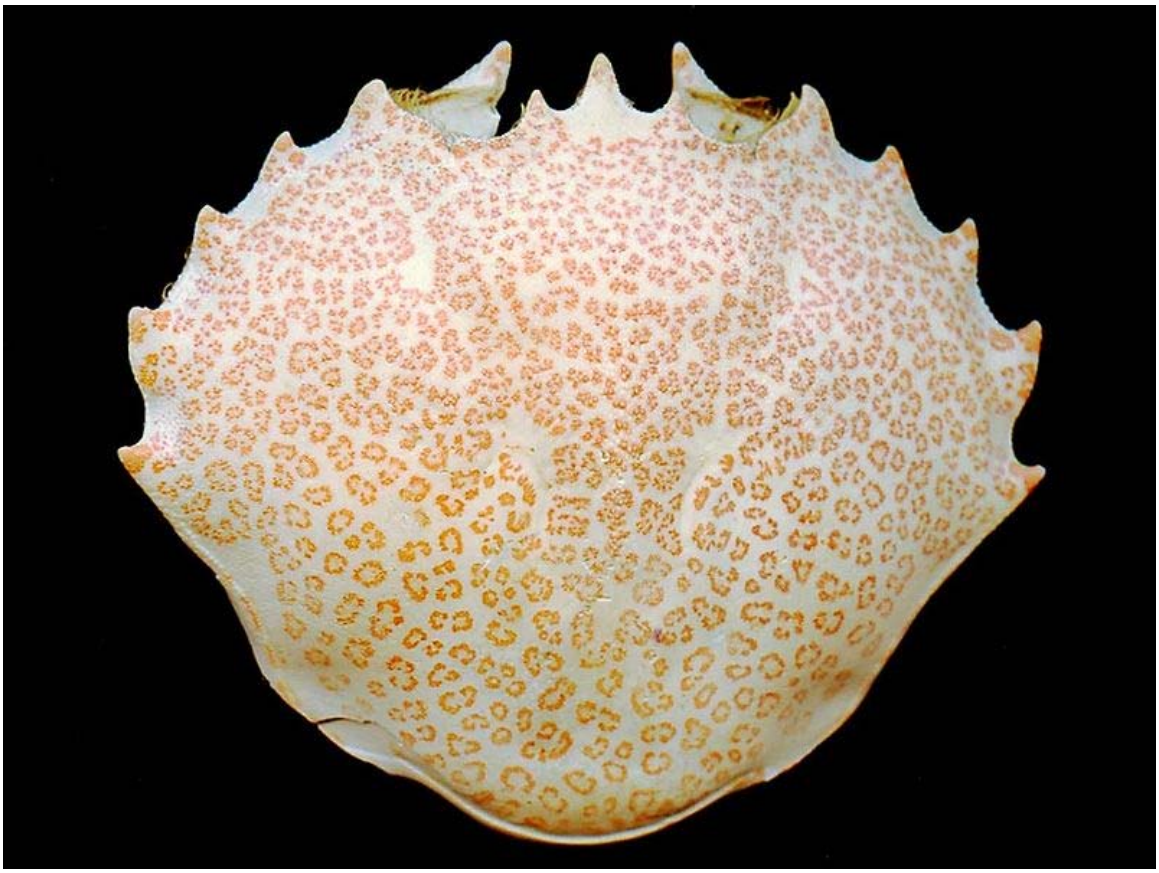

The molted carapace of a lady crab from Long Beach, New York

A molted carapace of *Cancer irroratus* from Long Beach, New York

A **carapace** is a dorsal (upper) section of the exoskeleton or shell in a number of animal groups, including arthropods such as crustaceans and arachnids as well as vertebrates such as turtles and tortoises. In turtles and tortoises, the underside is called the plastron.

Crustaceans

In crustaceans, the carapace is a part of the exoskeleton that covers the cephalothorax. It is particularly well developed in lobsters and crabs.

The carapace functions as a protective cover over the cephalothorax. Where it projects forward beyond the eyes, this projection is called a rostrum. The carapace is calcified to varying degrees in different crustaceans.

Zooplankton within the phylum Crustacea also have a carapace. These include Cladocera, Copepods, Ostracods, and Isopods, however Isopods only have a developed "cephalic shield" carapace covering the head.

Arachnida

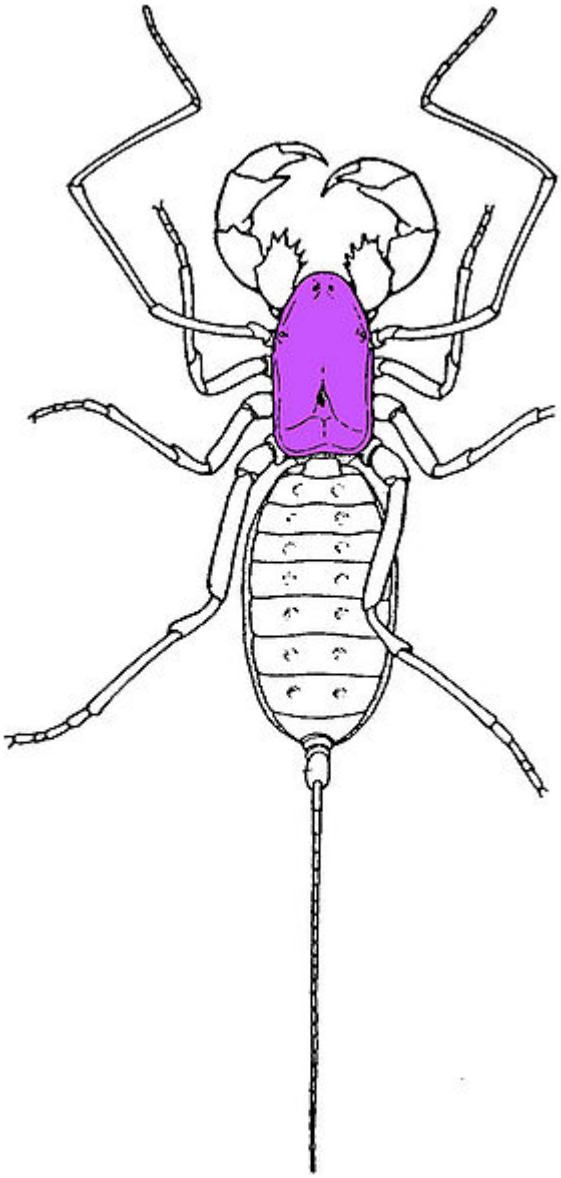

Diagram of an arachnid, with the carapace highlighted in purple

In arachnids, the carapace is formed by the fusion of prosomal tergites into a single plate which carries the eyes, ocularium, ozopores (a pair of openings of the scent gland of Opiliones) and diverse phaneres.

In a few orders, such as Solifugae and Schizomida the carapace may be subdivided. In Opiliones some authors prefer to use the term carapace interchangeably with the term cephalothorax, which is incorrect usage, because carapace refers only to the dorsal part of the exoskeleton of the cephalothorax.

An alternative term for the carapace of arachnids and their relatives, which avoids confusion with crustaceans, is **prosomal dorsal shield**.

Turtles and tortoises

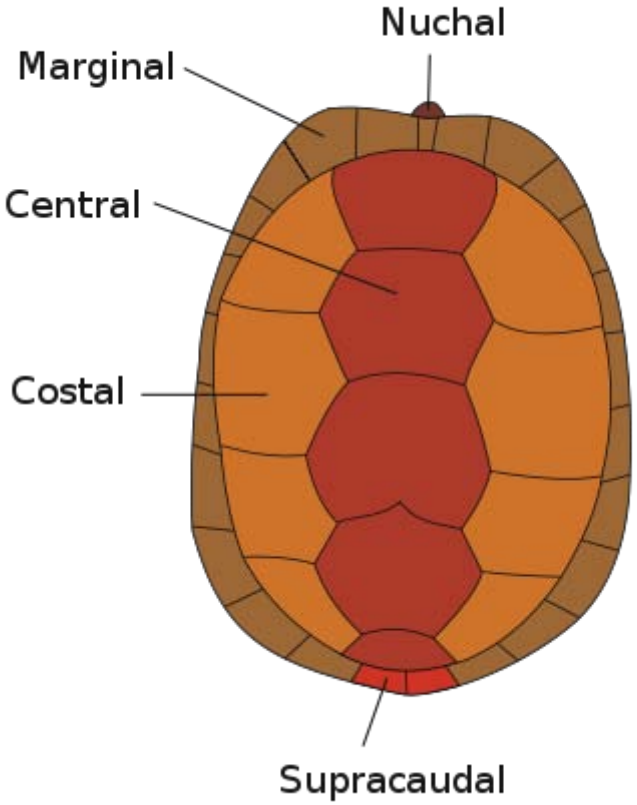

The scutes of a turtle's carapace

The **carapace** is the dorsal, convex part of the shell structure of a turtle, consisting primarily of the animal's broad ribcage. The spine and ribs are fused to bony plates beneath the skin which interlock to form a hard shell. Exterior to the skin the shell is covered by scutes, which are horny plates made of keratin that protect the shell from scrapes and bruises.

Turtles can survive surprisingly severe injuries to the carapace, and even deep cracks or missing portions can fill in with bone and heal. The softshell turtles, pig-nose turtle and leatherback sea turtle lack scutes and the bony carapace is covered only by skin.

The carapaces of many species of turtles are brightly colored and patterned and allow individuals to identify others of their species at a distance. The scutes of the carapace grow outward in concentric circles similar to the growth rings on a tree as the turtle or tortoise grows. These rings typically correspond to one year of growth and can be used to estimate the age of an individual. The plastron makes up the lower half of a turtle's shell.

Chapter- 3

Exoskeleton

The discarded exoskeleton of a dragonfly nymph

An **exoskeleton** is an external skeleton that supports and protects an animal's body, in contrast to the internal skeleton (endoskeleton) of, for example, a human. In popular usage, some of the larger kinds of exoskeletons are known as "**shells**". Some examples of

exoskeleton animals include insects such as grasshoppers and cockroaches, and crustaceans such as crabs and lobsters. The shells of the various groups of shelled mollusks, including those of snails, clams, tusk shells, chitons and nautilus are also exoskeletons.

Mineralized exoskeletons first appeared in the fossil record about 550 million years ago, and their evolution is considered by some to have played a role in the subsequent Cambrian explosion of animals.

Some animals, such as the tortoise, have both an endoskeleton and an exoskeleton.

Role of the exoskeleton

Exoskeletons contain rigid and resistant components that fulfil a set of functional roles including protection, excretion, sensing, support, feeding and acting as a barrier against desiccation in terrestrial organisms. Exoskeletons have a role in defence from pests and predators, support, and in providing an attachment framework for musculature.

Exoskeletons contain chitin and when calcium carbonate is added, the exoskeleton grows in strength and hardness.

Diversity

Many taxa produce exoskeletons, which are composed of a range of materials. Bone, cartilage, or dentine is used in the Ostracoderm fish and turtles. Chitin forms the exoskeleton in arthropods including insects, arachnids such as spiders, crustaceans such as crabs and lobsters, and in some fungi and bacteria. Calcium carbonates constitute the shells of molluscs, brachiopods, and some tube-building polychaete worms. Silica forms the exoskeleton in the microscopic diatoms and radiolaria.

Some organisms, such as some foraminifera, agglutinate exoskeletons by sticking grains of sand and shell to their exterior. Contrary to a common misconception, echinoderms do not possess an exoskeleton, as their test is always contained within a layer of living tissue.

Exoskeletons have evolved independently many times; 18 lineages evolved calcified exoskeletons alone. Further, other lineages have produced tough outer coatings analogous to an exoskeleton, such as some mammals – (constructed from bone in the armadillo, and hair in the pangolin) – and reptiles (turtle and Ankylosaur armor are constructed of bone; crocodiles have bony scutes and horny scales).

Growth in an exoskeleton

Since exoskeletons are rigid, they present some limits to growth. Some organisms grow by adding new material to the aperture of their shell, but many must moult their shell when they outgrow it, producing a replacement.

Palaeontological significance

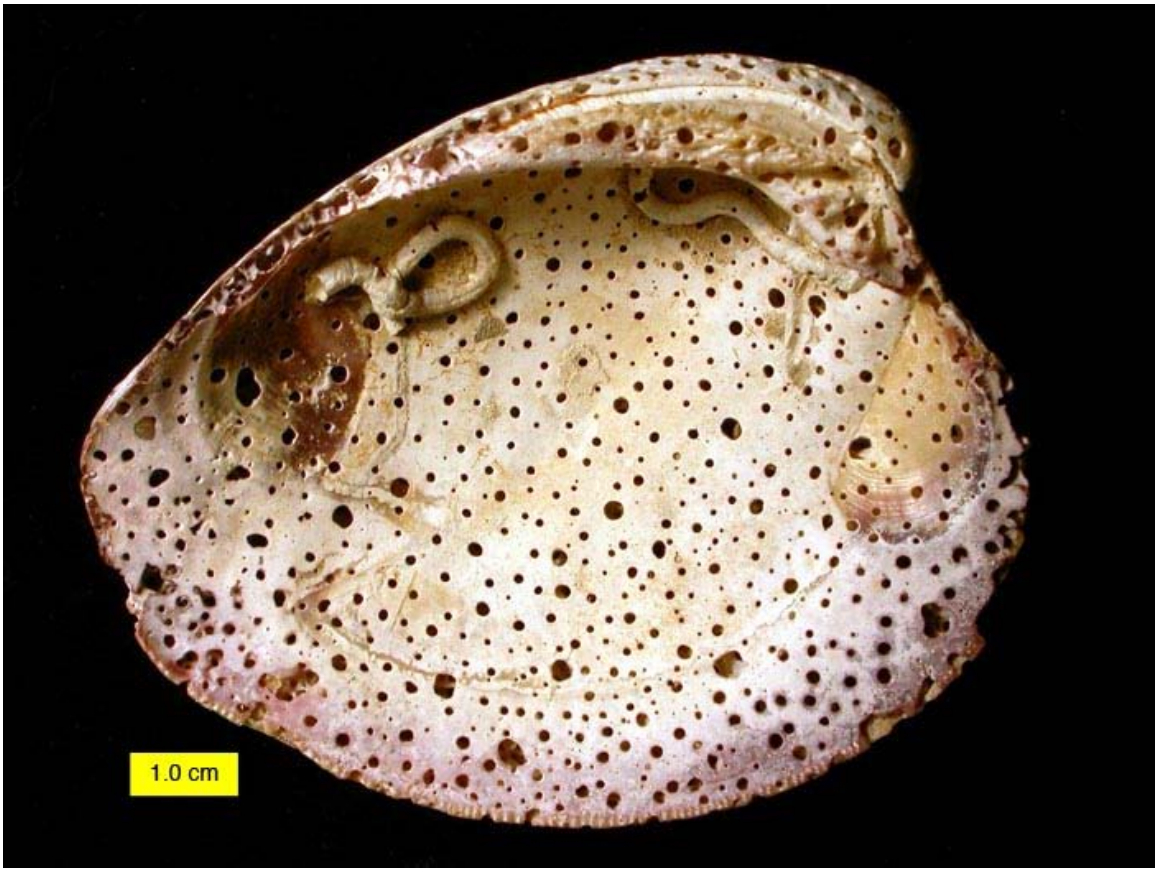

Borings in exoskeletons can provide evidence of animal behavior. In this case, boring sponges attacked this hard clam shell after the death of the clam, producing the trace fossil *Entobia*.

Exoskeletons, as hard parts of organisms, are greatly useful in assisting preservation of organisms, whose soft parts usually rot before they can be fossilized. Mineralized exoskeletons can be preserved "as is", as shell fragments, for example. The possession of an exoskeleton also permits a couple of other routes to fossilization. For instance, the tough layer can resist compaction, allowing a mold of the organism to be formed underneath the skeleton, which may later decay. Alternatively, exceptional preservation may result in chitin being mineralized, as in the Burgess Shale, or transformed to the resistant polymer keratin, which can resist decay and be recovered.

However our dependence on fossilized skeletons also significantly limits our understanding of evolution. Only the parts of organisms that were already mineralized are usually preserved, such as the shells of mollusks. It helps that exoskeletons often contain "muscle scars", marks where muscles have been attached to the exoskeleton, which may allow the reconstruction of much of an organism's internal parts from its exoskeleton alone. The most significant limitation is that, although there are 30-plus phyla of living animals, two-thirds of these phyla have never been found as fossils, because most animal species are soft-bodied and decay before they can become fossilized.

Mineralized skeletons first appear in the fossil record shortly before the base of the Cambrian period, 550 million years ago. The evolution of a mineralized exoskeleton is seen by some as a possible driving force of the Cambrian explosion of animal life, resulting in a diversification of predatory and defensive tactics. However, some Precambrian (Ediacaran) organisms produced tough outer shells, while others, such as *Cloudina*, had a calcified exoskeleton. Some *Cloudina* shells even show evidence of predation, in the form of borings.

Evolution

On the whole, the fossil record only contains mineralised exoskeletons, since these are by far the most durable. Since most lineages with exoskeletons are thought to have started out with a non-mineralised exoskeleton which they later mineralised, this makes it difficult to comment on the very early evolution of each lineage's exoskeleton. We do know that in a very short course of time just before the Cambrian period exoskeletons made of various materials – silica, calcium phosphate, calcite, aragonite, and even glued-together mineral flakes – sprang up in a range of different environments. Most lineages adopted the form of calcium carbonate which was stable in the ocean at the time they first mineralissd, and did not change from this mineral morph - even when it became the less favorable.

Some Precambrian (Ediacaran) organisms produced tough but non-mineralized outer shells, while others, such as *Cloudina*, had a calcified exoskeleton, but mineralized skeletons did not become common until the beginning of the Cambrian period, with the rise of the "small shelly fauna". Just after the base of the Cambrian, these miniature fossils become diverse and abundant – this abruptness may be an illusion, since the chemical conditions which preserved the small shellies appeared at the same time. Most other shell forming organisms appear during the Cambrian period, with the Bryozoans being the only calcifying phylum to appear later, in the Ordovician. The sudden appearance of shells has been linked to a change in ocean chemistry which made the calcium compounds of which the shells are constructed stable enough to be precipitated into a shell. However this is unlikely to be a sufficient cause, as the main construction cost of shells is in creating the proteins and polysaccharides required for the shell's composite structure, not in the precipitation of the mineral components. Skeletonisation also appeared at almost exactly the same time that animals started burrowing to avoid predation, and one of the earliest exoskeletons was made of glued-together mineral flakes, suggesting that skeletonisation was likewise a response to increased pressure from predators.

Ocean chemistry may also control which mineral shells are constructed of. Calcium carbonate has two forms, the stable calcite, and the metastable aragonite, which is stable within a reasonable range of chemical environments but rapidly becomes unstable outside this range. When the oceans contain a relatively high proportion of magnesium compared to calcium, aragonite is more stable, but as the magnesium concentration drops, it becomes less stable, hence harder to incorporate into an exoskeleton, as it will tend to dissolve.

With the exception of the mollusks, whose shells often comprise both forms, most lineages use just one form of the mineral. The form used appears to reflect the seawater chemistry – thus which form was more easily precipitated – at the time that the lineage first evolved a calcified skeleton, and does not change thereafter. However, the relative abundance of calcite- and aragonite-using lineages does not reflect subsequent seawater chemistry – the magnesium/calcium ratio of the oceans appears to have a negligible impact on organisms' success, which is instead controlled mainly by how well they recover from mass extinctions. A recently-discovered modern gastropod that lives near deep-sea hydrothermal vents illustrates the influence of both ancient and modern local chemical environments: its shell is made of aragonite, which is found in some of the earliest fossil mollusks; but it also has armor plates on the sides of its foot, and these are mineralized with the iron sulfides pyrite and greigite, which had never previously been found in any metazoan but whose ingredients are emitted in large quantities by the vents.

Artificial "exoskeletons"

Humans have long used armor as an artificial exoskeleton for protection, especially in combat. Exoskeletal machines (also called powered exoskeletons) are also starting to be used for medical and industrial purposes, while powered human exoskeletons are a feature of science fiction writing, but are currently moving into prototype stage.

Orthoses are a limited, medical form of exoskeleton. An orthosis (plural *orthoses*) is a device which attaches to a limb, or the torso, to support the function or correct the shape of that limb or the spine. Orthotics is the field dealing with orthoses, their use, and their manufacture. An orthotist is a person who designs and fits orthoses. A prosthesis (plural *prostheses*) is a device that substitutes for a missing part of a limb. If the prosthesis is a hollow shell and self-carrying, it is exoskeletal. If internal tubes are used in the device and the cover (cosmesis) to create the outside shape is made of a soft, non-carrying material, it is endoskeletal. Prosthetics is the field that deals with prostheses, use, and their manufacture. A prosthetist is a person who designs and fits prostheses.

Parenthetically, the exoskeleton has been used as an architectural model.

Perhaps the first animals to use a naturally-occurring "artificial exoskeleton" were the hermit crabs, the majority of which are obliged constantly to "wear" an empty gastropod shell, in order to protect their soft abdomens.

Chapter- 4

Cat Anatomy

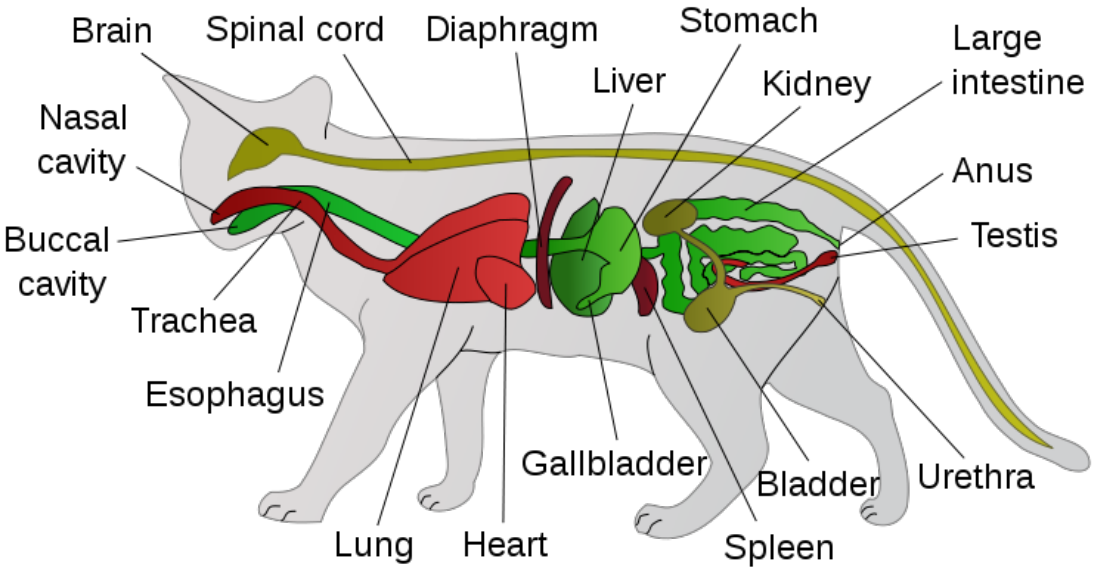

Diagram of the general anatomy of a male cat

General characteristics

Mouth

Cats have highly specialized teeth for the killing of prey and the tearing of meat. The *premolar* and *first molar* together compose the *carnassial pair* on each side of the mouth, which efficiently functions to shear meat like a pair of scissors. While this is present in canids, it is highly developed in felines. The cat's tongue has sharp spines, or *papillae*, useful for retaining and ripping flesh from a carcass. These papillae are small backward-facing hooks that contain keratin which also assist in their grooming.

As facilitated by their oral structures, cats use a variety of vocalizations for communication, including meowing, purring, hissing, growling, squeaking, chirping,

clicking, and grunting. Their types of body language: position of ears and tail, relaxation of whole body, kneading of paws, all are indicators of mood.

Ears

Thirty-two individual muscles in each ear allow for a manner of directional hearing; a cat can move each ear independently of the other. Because of this mobility, a cat can move its body in one direction and point its ears in another direction. Most cats have straight ears pointing upward. Unlike dogs, flap-eared breeds are extremely rare (*Scottish Folds* are one such exceptional mutation). When angry or frightened, a cat will lay back its ears to accompany the growling or hissing sounds it makes. Cats also turn their ears back when they are playing or to listen to a sound coming from behind them. The angle of cats' ears is an important clue to their mood.

Legs

Cats, like dogs, are digitigrades. They walk directly on their toes, with the bones of their feet making up the lower part of the visible leg. Cats are capable of walking very precisely because like all felines, they directly register; that is, they place each hind paw (almost) directly in the print of the corresponding forepaw, minimizing noise and visible tracks. This also provides sure footing for their hind paws when they navigate rough terrain. The two back legs make the cat able to leap far distances and fall from high places without getting hurt.

Claws

Close-up of a cat's claw.

Like nearly all members of the family Felidae, cats have retractable claws. In their normal, relaxed position, the claws are sheathed with the skin and fur around the toe pads. This keeps the claws sharp by preventing wear from contact with the ground and allows the silent stalking of prey. The claws on the forefeet are typically sharper than those on the hind feet. Cats can voluntarily extend their claws on one or more paws. They may extend their claws in hunting or self-defense, climbing, "kneading", or for extra traction on soft surfaces (bedspreads, thick rugs, skin, etc.). It is also possible to make a cooperative cat extend its claws by carefully pressing both the top and bottom of the paw. The curved claws may become entangled in carpet or thick fabric, which may cause injury if the cat is unable to free itself.

Most cats have five claws on their front paws, and four or five on their rear paws. Because of an ancient mutation, however, domestic and feral cats are prone to polydactylyism, (particularly in the east coast of Canada and northeast coast of the United States) and may have six or seven toes. The fifth front claw (the *dewclaw*) is proximal to the other claws. There is a protrusion which appears to be a sixth "finger". This special feature of the front paws, on the inside of the wrists, is the carpal pad, also found on the paws of big cats and dogs. It has no function in normal walking, but is thought to be an anti-skidding device used while jumping.

Temperature and heart rate

Two cats curled up together.

The normal body temperature of a cat is between 38 and 39 °C (101 and 102.2 °F). A cat is considered *febrile* (hyperthermic) if it has a temperature of 39.5 °C (103 °F) or greater,

or *hypothermic* if less than 37.5 °C (100 °F). For comparison, humans have a normal temperature of approximately 36.8 °C (98.6 °F). A domestic cat's normal heart rate ranges from 140 to 220 beats per minute, and is largely dependent on how excited the cat is. For a cat at rest, the average heart rate usually is between 150 and 180 bpm, about twice that of a human (average 80 bpm).

Skin

Cats possess rather loose skin; this allows them to turn and confront a predator or another cat in a fight, even when it has a grip on them. This is also an advantage for veterinary purposes, as it simplifies injections. In fact, the lives of cats with kidney failure can sometimes be extended for years by the regular injection of large volumes of fluid subcutaneously, which serves as an alternative to dialysis.

The particularly loose skin at the back of the neck is known as the *scruff*, and is the area by which a mother cat grips her kittens to carry them. As a result, cats tend to become quiet and passive when gripped there. This behavior also extends into adulthood, when a male will grab the female by the scruff to immobilize her while he mounts, and to prevent her from running away as the mating process takes place.

This technique can be useful when attempting to treat or move an uncooperative cat. However, since an adult cat is heavier than a kitten, a pet cat should never be carried by the scruff, but should instead have its weight supported at the rump and hind legs, and at the chest and front paws. Often (much like a small child), a cat will lie with its head and front paws over a person's shoulder, and its back legs and rump supported under the person's arm.

Skeleton

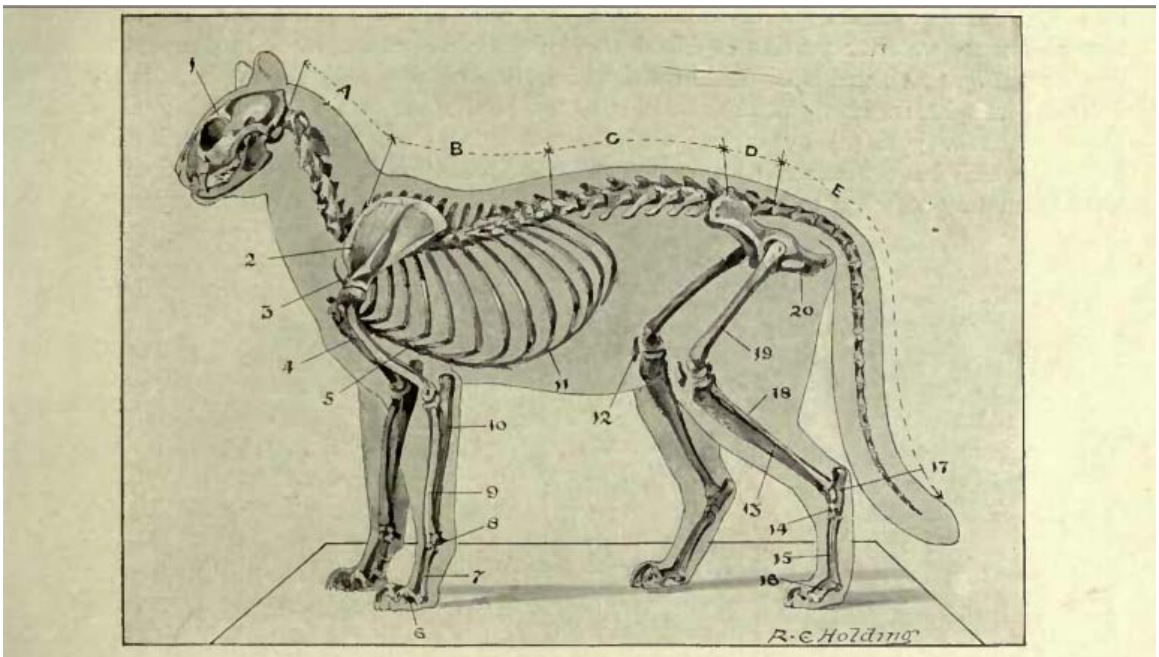

FIG. VIII.—SKELETON OF A CAT.

A. CERVICAL OR NECK BONES (7 in number). *B.* DORSAL OR THORACIC BONES (13 in number, each bearing a rib). *C.* LUMBAR BONES (7 in number). *D.* SACRAL BONES (3 in number). *E.* CAUDAL OR TAIL BONES (19 to 21 in number).

1.—Cranium, or Skull.
2.—Scapula, or Shoulder-blade.
3.—Clavicle, or Collar-bone.
4.—Humerus.
5.—Sternum, or Breast-bone.
6.—Phalanges of the Toes.
7.—Metacarpal Bones.
8.—Carpal or Wrist-bones.
9.—Radius.
10.—Ulna.
11.—Costal cartilages, uniting ends of Ribs to Sternum.
12.—Patella, or Knee-cap.
13.—Tibia.
14.—Tarsal Bones.
15.—Metatarsal Bones.
16.—Phalanges of Hind Toes.
17.—Heel-bone, or "Calcis."
18.—Fibula.
19.—Femur, or Thigh-bone.
20.—Pelvis, or Hip-bone.

Cats have 7 cervical vertebrae like almost all mammals, 13 thoracic vertebrae (humans have 12), 7 lumbar vertebrae (humans have 5), 3 sacral vertebrae (humans have 5 because of their bipedal posture), and, except for Manx cats, 22 or 23 caudal vertebrae (humans have 3 to 5, fused into an internal coccyx). The extra lumbar and thoracic vertebrae account for the cat's enhanced spinal mobility and flexibility, compared to humans. The caudal vertebrae form the *tail*, used by the cat as a counterbalance to the body during quick movements. Cats also have free-floating clavicle bones, which allows them to pass their body through any space into which they can fit their heads.

Muscles

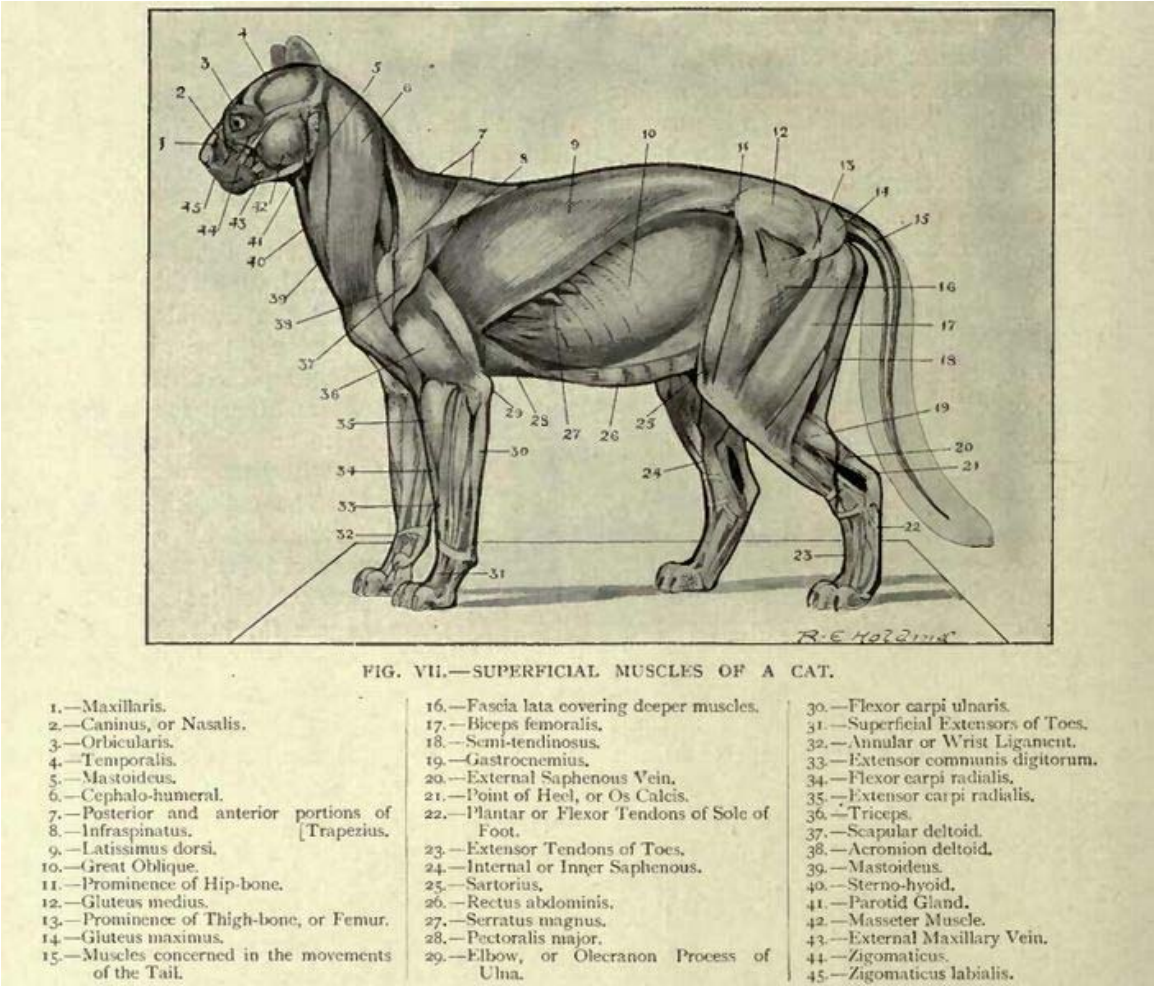

Abdominal

External Abdominal Oblique

This muscle's origin is the lumbodorsal fascia and ribs.

- Insertion: pubis and linea alba (via aponeurosis)
- Action: compresses abdominal contents; laterally flexes and rotates vertebral column

Internal Abdominal Oblique

This muscle's origin is the lumbodorsal fascia and pelvis.

- Insertion: linea alba (via aponeurosis)

- Action: compresses abdominal contents; laterally flexes and rotates vertebral column

Transversus Abdominis

This muscle is the innermost abdominal muscle.

- Origin: second sheet of the lumbodorsal fascia and the pelvic girdle
- Insertion: linea alba
- Action: compressor of the abdomen

Rectus Abdominis

To see this muscle, first remove the extensive aponeurosis situated on the ventral surface of the cat. Its fibers are extremely longitudinal, on each side of the linea alba. It is also traversed by the inscriptiones tendinae, or what others called *myosepta*.

Deltoid

The **deltoid muscles** lie just lateral to the trapezius muscles, originating from several fibers spanning the clavicle and scapula, converging to insert at the humerus. Anatomically, there are only two deltoids in the cat, the *acromiodeltoid* and the *spinodeltoid*. However, to conform to human anatomy standards, the clavobrachialis is now also considered a deltoid and is commonly referred to as the *clavodeltoid*.

Acromiodeltoid

The acromiodeltoid is the shortest of the deltoid muscles. It lies lateral to (to the side of) the clavodeltoid, and in a more husky cat it may only be seen by lifting or reflecting the clavodeltoid. It originates at the acromion process and inserts at the deltoid ridge. When contracted, it raises and rotates the humerus outward.

Spinodeltoid

A stout and short muscle lying posterior to the acromiodeltoid. It lies along the lower border of the scapula, and it passes through the upper arm, across the upper end of muscles of the upper arm. It originates at the spine of the scapula and inserts at the deltoid ridge. Its action is to raise and rotate the humerus outward.

Head

Masseter

The **Masseter** is a great, powerful, and very thick muscle covered by a tough, shining fascia lying ventral to the zygomatic arch, which is its origin. It inserts into the posterior half of the lateral surface of the mandible. Its action is the elevation of the mandible (closing of the jaw).

Temporalis

The **temporalis** is a great mass of mandibular muscle, and is also covered by a tough and shiny fascia. It lies dorsal to the zygomatic arch and fills the temporal fossa of the skull. It arises from the side of the skull and inserts into the coronoid process of the mandible. It too, elevates the jaw.

Integumental

The two main integumentary muscles of a cat are the *platysma* and the *cutaneous maximus*. The *cutaneous maximus* covers the dorsal region of the cat and allows it to shake its skin. The *platysma* covers the neck and allows the cat to stretch the skin over the pectoralis major and deltoid muscles.

Neck and back

Rhomboideus

The Rhomboideus is a thick, large muscle below the Trapezius muscles. It extends from the vertebral border of the scapula to the mid-dorsal line.

- Origin: neural spines of the first four thoracic vertebrae
- Insertion: vertebral border of the scapula
- Action: draws the scapula to the dorsal

Rhomboideus Capitis

The Rhomboideus capitis is the most cranial of the deeper muscles. It is underneath the Clavotrapezius.

- Origin: superior nuchal line
- Insertion: scapula

Splenius

The Splenius is the most superficial of all the deep muscles. It is a thin, broad sheet of muscle underneath the Clavotrapezius and deflecting it. It is crossed also by the Rhomboideus capitis. Its origin is the mid-dorsal line of the neck and fascia. The insertion is the superior nuchal line and atlas. It raises or turns the head.

Serratus Ventralis

The Serratus Ventralis is exposed by cutting the wing-like Latissimus Dorsi. The said muscle is covered entirely by adipose tissue. The origin is from the first nine or ten ribs and from part of the cervical vertebrae. The insertion is the vertebral border of the scapula. It draws scapula forward, backward, and against the body.

Serratus Dorsalis

The Serratus Dorsalis is medial to both the scapula and the Serratus Ventralis.

- Origin: apoeurosis following the length of the mid-dorsal line
- Insertion: dorsal portion of the last ribs
- Action: draws ribs cranial

Intercostals

The Intercostals are a set of muscles sandwiched between the ribs. They interconnect ribs, and are therefore the primary respiratory skeletal muscles. They are divided into the *external* and the *internal subscapularis*. The origin and insertion are in the ribs. The intercostals pull the ribs backwards or forwards.

Caudofemoralis

The Caudofemoralis is a muscle found in the pelvic limb and is unique to the felids (cats). The Caudofemoralis acts to flex the tail laterally to its respective side when the pelvic limb is bearing weight. When the pelvic limb is lifted off the ground, contraction of the Caudofemoralis causes the limb to abduct and the shank to extend by extending the hip joint.

Pectoral

Pectoantebrachialis

Pectoantebrachialis muscle is just one-half inch wide, and is the most superficial in the pectoral muscles.

- Origin: manubrium of the sternum
- Insertion: in a flat tendon on the fascia of the proximal end of the ulna
- Action: draws the arm towards the chest

Pectoralis Major

The pectoralis major, also called *pectoralis superficialis*, is a broad triangular portion of the pectoralis muscle which is immediately below the pectoantebrachialis. It is actually smaller than the pectoralis minor muscle.

- Origin: sternum and median ventral raphe
- Insertion: humerus
- Action: draws the arm towards the chest

Pectoralis Minor

The pectoralis minor muscle is larger than the Pectoralis major. However, most of its anterior border is covered by the pectoralis major.

- Origin: ribs 3-5
- Insertion: coracoid process of scapula
- Action: tipping of the scapula, elevation of ribs 3-5

Xiphihumeralis

The most posterior, flat, thin, and long strip of pectoral muscle is the Xiphihumeralis. It is a band of parallel fibers that is found felines but not in humans. Its origin is the Xiphoid Process of the sternum. The insertion is the humerus.

Trapezius

In the cat there are three thin flat muscles that cover the back, and to a lesser extent, the neck. They pull the scapula toward the mid-dorsal line, anteriorly, and posteriorly.

Clavotrapezius

The most anterior of the trapezius muscles, it is also the largest. Its fibers run obliquely to the ventral surface.

- Origin: superior nuchal line and median dorsal line
- Insertion: clavicle
- Action: draws the clavicle dorsal and towards the head

Acromiotrapezius

Acromiotrapezius is the middle trapezius muscle. It covers the dorsal and lateral surfaces of the scapula.

- Origin: neural spines of the cervical vertebrae
- Insertion: in the metacromion process and fascia of clavotrapezius
- Action: draws the scapula to the dorsal, and holds the two scapula together

Spinotrapezius

Spinotrapezius, also called *thoracic trapezius*, is the most posterior of the three. It is triangular shaped. Posterior to the acromiotrapezius and overlaps latissimus dorsi on the front.

- Origin: neural spines of the thoracic vertebrae
- Insertion: scapular fascia
- Action: draws the scapula to the dorsal and caudal regions

Genitalia

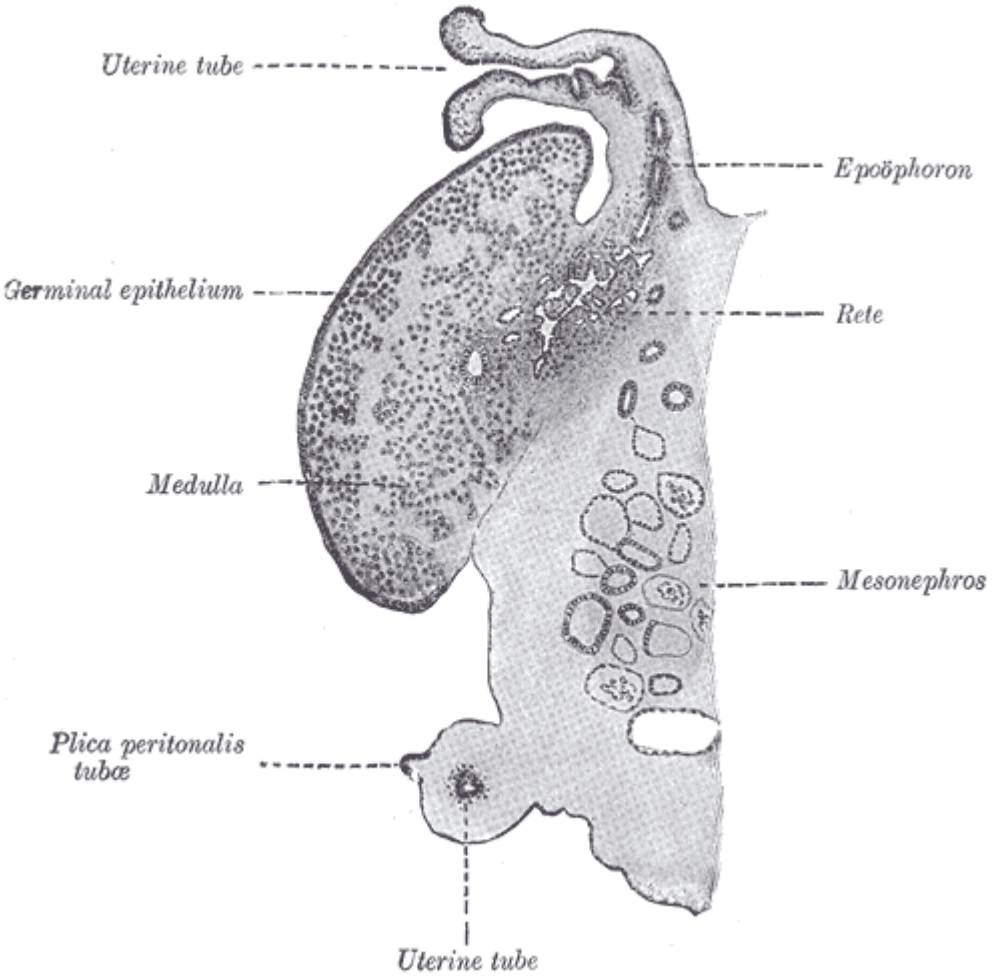

Longitudinal plane section of ovary of cat embryo of 9.4 cm. long. Seen is the cat version of uterine tube, epoophoron, germinal epithelium, rete, Medulla of ovary, mesonephros, plica peritonalis tubae

Female genitalia

In the female cat, the genitalia include:

- Two gonads
- Uterus
- Vagina
- Genital passages
- Teats

Together with the vulva, the vagina of cat is involved in mating and provides a channel for newborns during *parturition*, or birth. The vagina is long and wide. Genital passages are the oviducts of the cat. They are short, narrow, and not very sinuous.

Chapter- 5

Horn (Anatomy)

A goat with spiral horns

A **horn** is a pointed projection of the skin on the head of various animals, consisting of a covering of horn (keratin and other proteins) surrounding a core of living bone. True horns are found mainly among the ruminant artiodactyls, in the families Antilocapridae (pronghorn) and Bovidae (cattle, goats, antelope etc.). One pair of horns is usual, but two pairs occur in a few wild species and in a few domesticated breeds of sheep. Partial or deformed horns in livestock are called *scurs*.

Horns usually have a curved or spiral shape, often with ridges or fluting. In many species only males have horns. Horns start to grow soon after birth, and continue to grow throughout the life of the animal (except in pronghorns, which shed the outer layer annually, but retain the bony core). Similar growths on other parts of the body are not usually called horns, but spurs, claws or hoofs, depending on the part of the body on which they occur.

Other hornlike growths

The term "horn" is also popularly applied to other hard and pointed features attached to the head of animals in various other families:

- Giraffidae: Giraffes have one or more pairs of bony bumps on their heads, called ossicones. These are covered with furred skin.
- Cervidae: Most deer have antlers, which are not true horns. When fully developed, antlers are dead bone without a horn or skin covering; they are borne only by adults (usually males) and are shed and regrown each year.
- Rhinocerotidae: The "horns" of rhinoceroses are made of keratin and grow continuously, but do not have a bone core.
- Ceratopsidae: The "horns" of the *Triceratops* were extensions of its skull bones although debate exists over whether they had a keratin covering.
- Horned lizards (*Phrynosoma*): These lizards have horns on their heads which have a hard keratin covering over a bony core, like mammalian horns.
- Insects: Some insects (such as rhinoceros beetles) have horn-like structures on the head or thorax (or both). These are pointed outgrowths of the hard chitinous exoskeleton. Some (such as stag beetles) have greatly enlarged jaws, also made of chitin.
- Canidae: Golden jackals are known to occasionally develop a horny growth on the skull, which is associated with magical powers in south-eastern Asia.

Many mammal species in various families have tusks, which often serve the same functions as horns, but are in fact oversize teeth. These include the Moschidae (Musk deer, which are ruminants), Suidae (Wild Boars), Proboscidea (Elephants), Monodontidae (Narwhals) and Odobenidae (Walruses).

A Hebridean sheep with one horn on one side and two on the other.

Polled animals or *pollards* are those of normally-horned (mainly domesticated) species whose horns have been removed, or which have not grown. In some cases such animals have small horny growths in the skin where their horns would be – these are known as *scurs*.

On humans

Cutaneous horns are the only examples of horns growing on people. They are believed to be caused by exposure to radiation. They are most often benign growths and can be removed by a razor.

Cases of people with *naturally* growing horns have been historically described, sometimes propagated to mythical status. And there are several cases of photographic evidence to prove the phenomenon with modern science. There are human cadaveric specimens that show outgrowings, but these are instead classified as osteomas or other excrescences. Theoretically, there may be children born with horns which are corrected with early surgical intervention. The phenomenon of humans with horns has been observed in countries lacking such advanced medicine. There are even people living now, several in China, with cases of cutaneous horns, most common in the elderly.

Some people, notably The Enigma, have horn implants; that is, they have implanted silicone beneath the skin as a form of body modification.

Animal uses of horns



Both male and female African buffaloes bear horns

Animals have a variety of uses for horns and antlers, including defending themselves from predators and fighting members of their own species for territory, dominance or mating priority. Horns are usually present only in males but in some species, females too may possess horns. It has been theorized by researchers that taller species living in the open are more visible from longer distances and more likely to benefit from horns to defend themselves against predators. Female bovids that are not hidden from predators due to their large size or open Savannah like habitat are more likely to bear horns than small or camouflaged species.

In addition, horns may be used to root in the soil or strip bark from trees. In animal courtship many use horns in displays. For example, the male blue wildebeest reams the bark and branches of trees to impress the female and lure her into his territory. Some animals with true horns use them for cooling. The blood vessels in the bony core allow the horns to function as a radiator.

Human uses of horns

Water buffalo horn used as a hammer with cleaver to cut fish in southeast China.

- Horned animals are sometimes hunted so their mounted head or horns can be displayed as a hunting trophy or as decorative objects. This practice can be considered controversial, especially as some animals are threatened or endangered due to reduced populations partially from pressures of such hunting.

- Some cultures use bovid horns as musical instruments, for example the shofar. These have evolved into brass instruments in which, unlike the trumpet, the bore gradually increases in width through most of its length — that is to say, it is conical rather than cylindrical. These are called horns, though now made of metal.

- Drinking horns are bovid horns removed from the bone core, cleaned and polished and used as drinking vessels. It has been suggested that the shape of a natural horn was also the model for the rhyton, a horn-shaped drinking vessel.

- Powder horns were originally bovid horns fitted with lids and carrying straps, used to carry gunpowder. Powder flasks of any material may be referred to as powder horns.

- Antelope horns are used in traditional Chinese medicine.

- Horns consist of keratin, and the term "horn" is used to refer to this material, sometimes including similarly solid keratin from other parts of animals, such as hoofs. Horn may be used as a material in tools, furniture and decoration, among other uses. In these applications, horn is valued for its hardness, and it has given rise to the expression *hard as horn*. Horn is somewhat thermoplastic and (like tortoiseshell) was formerly used for many purposes where plastic would now be used. Horn may be used to make glue.

- Horn bows are bows made from a combination of horn, sinew and usually wood. These materials allow more energy to be stored in a short bow than wood alone.

- Ivory comes from the teeth of animals, not horns.

- "Horn" buttons are usually made from deer antlers, not true horn.

Chapter- 6

Metamorphosis

A dragonfly in its final moult, undergoing metamorphosis from its nymph form to an adult.

Metamorphosis is a biological process by which an animal physically develops after birth or hatching, involving a conspicuous and relatively abrupt change in the animal's body structure through cell growth and differentiation. Some insects, amphibians, molluscs, crustaceans, Cnidarians, echinoderms and tunicates undergo metamorphosis, which is usually accompanied by a change of habitat or behavior.

Scientific usage of the term is exclusive, and is not applied to general aspects of cell growth, including rapid growth spurts. References to "metamorphosis" in mammals are imprecise and only colloquial, but historically idealist ideas of transformation and monadology, as in Goethe's *Metamorphosis of Plants*, influenced the development of ideas of evolution.

Etymology

The word "metamorphosis" derives from Greek *μεταμόρφωσις*, "transformation, transforming", from *μετα-* (*meta-*), "change" + *μορφή* (*morphe*) "form".

Insect metamorphosis

All insects in the Pterygota undergo a marked change in form, or metamorphosis, from immature to adult. These insects either have hemimetabolous development, and undergo an incomplete or partial metamorphosis, or holometabolous development, which undergo a complete metamorphosis, including a pupal or resting stage between the larval and adult forms.

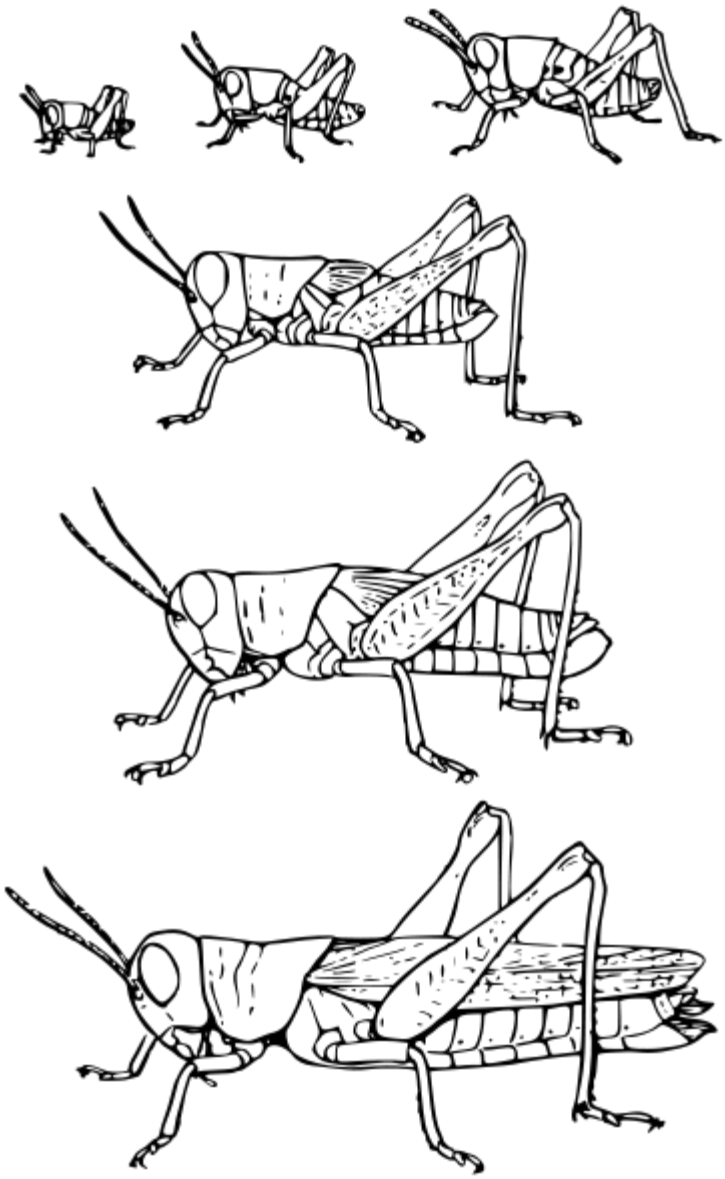

Incomplete metamorphosis in the grasshopper with different instar nymphs

In hemimetabolous insects, immature stages are called nymphs. Development proceeds in repeated stages of growth and ecdysis (moulting); these stages are called instars. The juvenile forms closely resemble adults, but are smaller and lack adult features such as wings and genitalia. This process is also known as "partial" or "incomplete" metamorphosis. The differences between nymphs in different instars are small, often just differences in body proportions and the number of segments, although external wing buds will form in later instars.

In holometabolous insects, immature stages are called larvae, and differ markedly from the adults. Insects which undergo holometabolism pass through a larval stage, then enter an inactive state called pupa, or chrysalis, and finally emerge as adults. This process is

called "complete" metamorphosis. Whilst inside the pupa, the insect will excrete digestive juices, to destroy much of the larva's body, leaving a few cells intact. Some of the remaining cells will begin the growth of the adult, using the nutrients from the broken down larva. This process of cell death is called histolysis, and cell regrowth histogenesis.

According to latest researches, adult Manduca sexta is able to retain the behaviour learned as a caterpillar.

Many observations have indicated that programmed cell death plays a considerable role during physiological processes of multicellular organisms, particularly during embryogenesis and metamorphosis.

Pieris rapae larva

Pieris rapae pupa

Pieris rapae pupa, ready to hatch.

A *Pieris rapae* adult

Hormonal control

Insect growth and metamorphosis are controlled by hormones synthesized by endocrine glands near the front of the body.

Neurosecretory cells in an insect's brain secrete a hormone, the prothoracicotropic hormone (PTTH) that activates prothoracic glands, which secrete a second hormone, usually Ecdysone (a ecdysteroid), that induces ecdysis.

PTTH also stimulates the corpora allata, a retrocerebral organ, to produce juvenile hormone (JH), which prevents the development of adult characteristics during ecdysis. In holometabolous insects, molts between larval instars have a high level of JH, the moult to the pupal stage has a low level of JH, and the final, or imaginal, molt has no JH present at all.

Amphibian metamorphosis

Just before metamorphosis, only 24 hours are needed to reach the stage in the next picture

Almost functional common frog with some remains of the gill sac and a not fully developed jaw

In typical amphibian development, eggs are laid in water and larvae are adapted to an aquatic lifestyle. Frogs, toads, and newts all hatch from the egg as larvae with external gills. Afterwards, newt larvae start a predatory lifestyle, while tadpoles mostly scrape food off surfaces with their horny tooth ridges.

Metamorphosis in amphibians is regulated by thyroxin concentration in the blood, which stimulates metamorphosis, and prolactin, which counteracts its effect. Specific events are dependent on threshold values for different tissues. Because most embryonic development is outside the parental body, development is subject to many adaptations due to specific ecological circumstances. For this reason tadpoles can have horny ridges for teeth, whiskers, and fins. They also make use of the lateral line organ. After metamorphosis, these organs become redundant and will be resorbed by controlled cell death, called apoptosis. The amount of adaptation to specific ecological circumstances is remarkable, with many discoveries still being made.

Frogs and toads

With frogs and toads, the external gills of the newly hatched tadpole are covered with a gill sac after a few days, and lungs are quickly formed. Front legs are formed under the gill sac, and hindlegs are visible a few days later. Following that there is usually a longer stage during which the tadpole lives off a vegetarian diet. Tadpoles use a relatively long, spiral‐shaped gut to digest that diet.

Rapid changes in the body can then be observed as the lifestyle of the frog changes completely. The spiral‐shaped mouth with horny tooth ridges is resorbed together with the spiral gut. The animal develops a big jaw, and its gills disappear along with its gill sac. Eyes and legs grow quickly, a tongue is formed, and all this is accompanied by associated changes in the neural networks (development of stereoscopic vision, loss of the lateral line system, etc.) All this can happen in about a day, so it is truly a metamorphosis. It isn't until a few days later that the tail is reabsorbed, due to the higher thyroxin concentrations required for tail resorption.

Newts

The large external gills of the crested newt

In newts, there is no true metamorphosis because newt larvae already feed as predators and continue doing so as adults. Newts' gills are never covered by a gill sac and will be resorbed only just before the animal leaves the water. Just as in tadpoles, their lungs are functional early, but newts don't make as much use of them as tadpoles do. Newts often have an aquatic phase in spring and summer, and a land phase in winter. For adaptation to a water phase, prolactin is the required hormone, and for adaptation to the land phase, thyroxin. External gills do not return in subsequent aquatic phases because these are completely absorbed upon leaving the water for the first time.

Metamorphosis in fish and invertebrate aquatic animals

Little known is that also fish, i.e. bony fish, undergo metamorphosis. Fish metamorphosis is typically under strong control by thyroid hormone. Examples include the agnatha, salmon, and lamprey, which must change from a freshwater to saltwater lifestyle (diadromous). Additionally, the flatfish begins its life bilaterally symmetrical, and one eye must move to join the other side of the fish in its adult form. The European eel has a number of metamorphoses, from the larval stage to the leptocephalus stage, then a quick outspoken metamorphosis from leptocephalus to glass eel at the edge of the continental shelf (8 days for Japanese eel), two months at the border of fresh and salt water the glass eel undergoes a quick metamorphosis into elver, which then has a long stage of growth followed by a more gradual metamorphosis to the migrating phase. In the pre-adult fresh water stage it also has phenotypic plasticity because fish eating eels develop very wide mandibles, making the head look blunt. Leptocephali are very common and a common phase for all Elopomorpha (Tarpon- and eellike fishes). Most bony fishes undergo metamorphosis after absorption of the yolk sac because after that phase they need to be able to feed for themselves.

Chapter- 7

Dog Anatomy

Dog anatomy includes the same internal structures that are in humans. Details of structures vary tremendously from breed to breed, more than in any other animal species, wild or domesticated, as dogs vary from the tiny Chihuahua to the giant Irish Wolfhound.

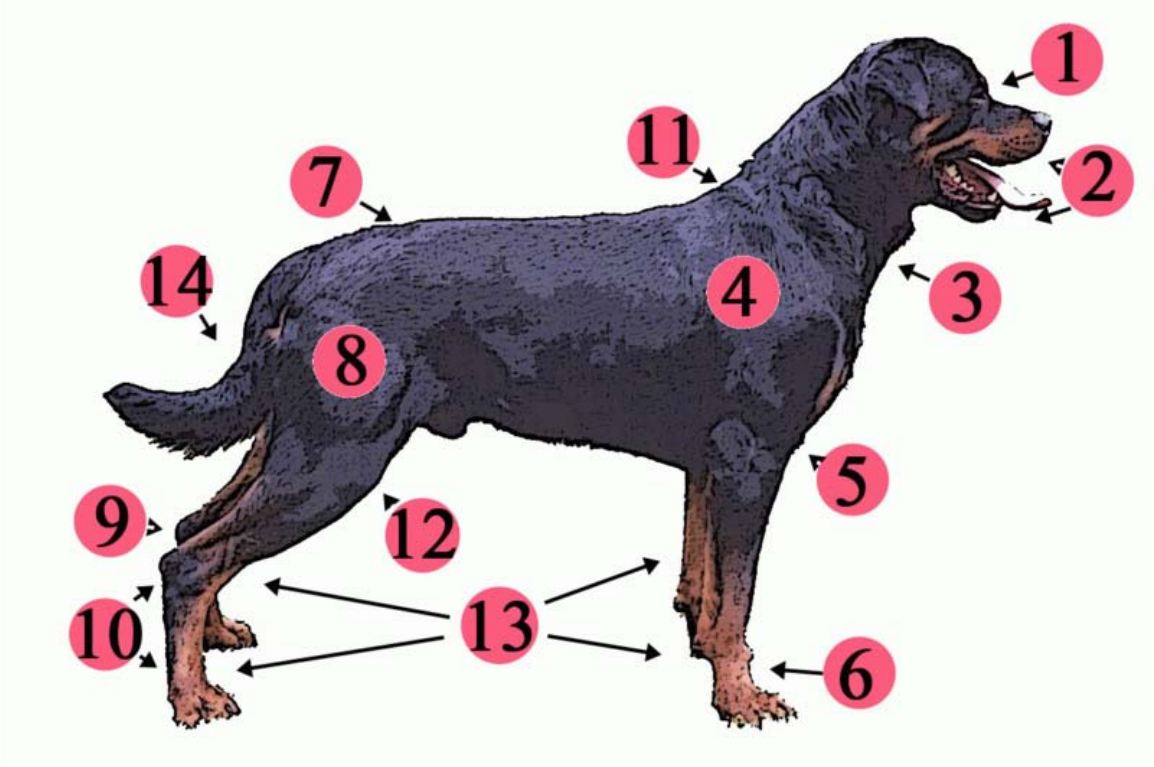

Croup 8.Leg (thigh and hip) 9.Hock 10.Hind feet 11.Withers 12.Stifle 13.Paws 14.Tail

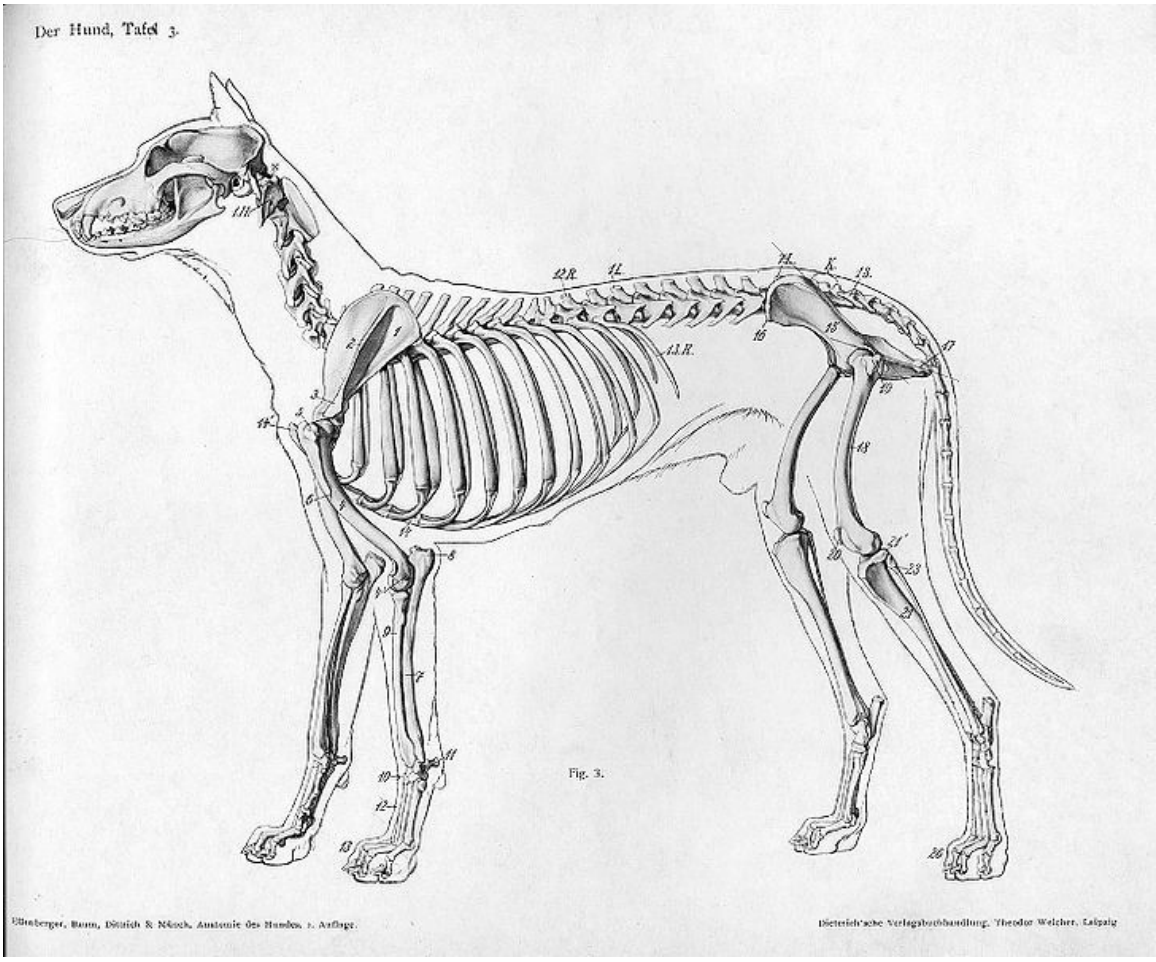

Skeleton of a domestic dog

Skull of a dog

Physical characteristics

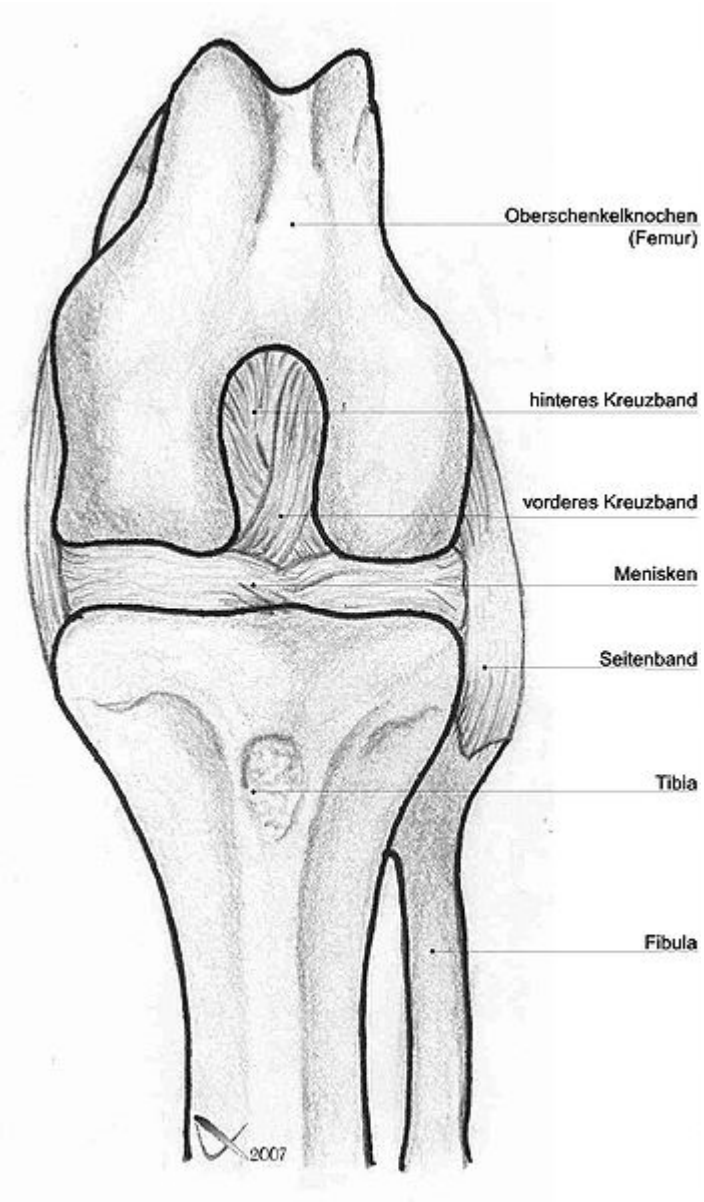

Dog knee

Like most predatory mammals, the dog has powerful muscles, a cardiovascular system that supports both sprinting and endurance, and teeth for catching, holding, and tearing.

The dog's ancestral skeleton provided the ability to run and leap. Their legs are designed to propel them forward rapidly, leaping as necessary, to chase and overcome prey. Consequently, they have small, tight feet, walking on their toes; their rear legs are fairly rigid and sturdy; the front legs are loose and flexible, with only muscle attaching them to the torso.

Although selective breeding has changed the appearance of many breeds, all dogs retain the basic ingredients from their distant ancestors. Dogs have disconnected shoulder bones (lacking the collar bone of the human skeleton) that allow a greater stride length for running and leaping. They walk on four toes, front and back, and have vestigial dewclaws (dog thumbs) on their front legs and sometimes on their rear legs.When a dog has extra dewclaws in addition to the usual one on each front leg, the dog is said to be "double dewclawed".

There is some debate about whether a dewclaw helps dogs to gain traction when they run because, in some dogs, the dewclaw makes contact when they are running and the nail on the dewclaw often wears down in the same way that the nails on their other toes do, from contact with the ground. However, in many dogs the dewclaws never make contact with the ground; in this case, the dewclaw's nail never wears away, and it is then often trimmed to keep it to a safe length.

The dewclaws are not dead appendages. They can be used to lightly grip bones and other items that dogs hold with the paws. However, in some dogs these claws may not appear to be connected to the leg at all except by a flap of skin; in such dogs the claws do not have a use for gripping as the claw can easily fold or turn.

There is also some debate as to whether dewclaws should be surgically removed. The argument for removal states that dewclaws are a weak digit, barely attached to the leg, so that they can rip partway off or easily catch on something and break, which can be extremely painful and prone to infection. Others say the pain of removing a dewclaw is far greater than any other risk. For this reason, removal of dewclaws is illegal in many countries. There is, perhaps, an exception for hunting dogs, who can sometimes tear the dewclaw while running in overgrown vegetation. If a dewclaw is to be removed, this should be done when the dog is a puppy, sometimes as young as 3 days old, though it can also be performed on older dogs if necessary (though the surgery may be more difficult then). The surgery is fairly straight-forward and may even be done with only local anesthetics if the digit is not well connected to the leg. Unfortunately many dogs can't resist licking at their sore paws following the surgery, so owners need to remain vigilant.

In addition, for those dogs whose dewclaws make contact with the ground when they run, it is possible that removing them could be a disadvantage for a dog's speed in running and changing of direction, particularly in performance dog sports such as dog agility.

The dog's ancestor was about the size of a Dingo, and its skeleton took about 10 months to mature. Today's toy breeds have skeletons that mature in only a few months, while giant breeds such as the Mastiffs take 16 to 18 months for the skeleton to mature. Dwarfism has affected the proportions of some breeds' skeletons, as in the Basset Hound.

Knowledge of basic anatomy also helps when competing in dog shows or contests.

Size

Researchers have identified a particular piece of genetic material that is common to every small-dog breed and, in turn, is probably responsible for making them tiny. The study, published in 2007, found a regulatory sequence (not a gene) next to the gene IGF1; together the gene and regulatory sequence together are known as a haplotype that "is a major contributor to body size in all small dogs." Medium and large size dogs do not usually have the regulatory sequence, although the small-size sequence was found in the Rottweiler breed. The study included 3,241 dogs from 143 breeds. The researchers concluded the genetic instructions to make dogs small must be at least 12,000 years old, and it is not found in wolves. Another study has shown that lap dogs (small dogs) are among the oldest dog types.

Modern dog breeds show more variation in size, appearance, and behavior than any other domestic animal. Within the range of extremes, dogs generally share attributes with their wild ancestors, the wolves. Dogs are predators and scavengers, possessing sharp teeth and strong jaws for attacking, holding, and tearing their food. Although selective breeding has changed the appearance of many breeds, all dogs retain basic traits from their distant ancestors. Like many other predatory mammals, the dog has powerful muscles, fused wristbones, a cardiovascular system that supports both sprinting and endurance, and teeth for catching and tearing.

Sight

A Greyhound, one of many breeds of sighthound

Like most mammals, dogs are dichromats and have color vision equivalent to red-green color blindness in humans. Different breeds of dogs have different eye shapes and dimensions, and they also have different retina configurations. Dogs with long noses have a "*visual streak*" which runs across the width of the retina and gives them a very wide field of excellent vision, while those with short noses have an "*area centralis*" — a central patch with up to three times the density of nerve endings as the *visual streak* — giving them detailed sight much more like a human's.

Some breeds, particularly the sighthounds, have a field of vision up to 270° (compared to 180° for humans), although broad-headed breeds with short noses have a much narrower field of vision, as low as 180°.

Hearing

According to hypertextbook.com, the frequency range of dog hearing is approximately 40 Hz to 60,000 Hz. Dogs detect sounds as low as the 16 to 20 Hz frequency range (compared to 20 to 70 Hz for humans) and above 45 kHz (compared to 13 to 20 kHz for humans), and in addition have a degree of ear mobility that helps them to rapidly pinpoint the exact location of a sound. Eighteen or more muscles can tilt, rotate and raise or lower a dog's ear. Additionally, a dog can identify a sound's location much faster than a human can, as well as hear sounds up to four times the distance that humans are able to. Those with more natural ear shapes, like those of wild canids like the fox, generally hear better than those with the floppier ears of many domesticated species.

Smell

Scent hounds, especially the Bloodhound, are bred for their keen sense of smell.

Dogs have nearly 220 million smell-sensitive cells over an area about the size of a pocket handkerchief (compared to 5 million over an area the size of a postage stamp for humans). According to nhm.org, dogs can sense odours at concentrations nearly 100 million times lower than humans can. According to Dummies.com, the percentage of the dog's brain that is devoted to analyzing smells is actually 40 times larger than that of a human. Some dog breeds have been selectively bred for excellence in detecting scents, even compared to their canine brethren.

The highly sensitive nose of a dog.

Coat

Domestic dogs often display the remnants of counter-shading, a common natural camouflage pattern. The general theory of countershading is that an animal that is lit from above will appear lighter on its upper half and darker on its lower half where it will usually be in its own shade. This is a pattern that predators can learn to watch for. A countershaded animal will have dark coloring on its upper surfaces and light coloring below. This reduces the general visibility of the animal. One reminder of this pattern is that many breeds will have the occasional "blaze", stripe, or "star" of white fur on their chest or undersides.

Dogs diverged from a now-extinct Asian wolf between 12,000 and 15,000 years ago, according to recent DNA studies. In that time, the long nose and heavy grey-colored double coat of the wolf has changed into the wide variety of dog shapes and coats and colors seen today. The change was due at first to genetic changes that occurred as the original dogs learned to tolerate the presence of humans, as shown in the research on foxes by Dmitri Belyaev in his Farm-Fox Experiment. The research found that a genetic change to tameness brought along other unexpected changes as well; one notable change was in the coats, changed from a typical fox coat to a spotted coat resembling a dog's

coat. As ancient dogs learned to live near humans and became less like wolves, their appearance changed as well, long before any selective breeding was done by people.

A Stanford University School of Medicine study published in Science in October, 2007 found the genetics that explain coat colors in other mammals such as in horse coats and in cat coats, did not apply to dogs. The project took samples from 38 different breeds to find the gene (a beta defensin gene) responsible for dog coat color. One version produces yellow dogs, and a mutation produces black. All dog coat colors are modifications of black or yellow. For example, the white in white miniature schnauzers is a cream color, not albinism (a genotype of e/e at MC1R.)

Modern dog breeds exhibit a diverse array of fur coats, including dogs without fur, such as the Mexican Hairless Dog. Dog coats vary in texture, color, and markings, and a specialized vocabulary has evolved to describe each characteristic.

Tail

There are many different shapes for dog tails: straight, straight up, sickle, curled, cork-screw. In some breeds, the tail is traditionally docked to avoid injuries (especially for hunting dogs). It can happen that some puppies are born with a short tail or no tail in some breeds.

Puppy characteristics

This probably 15 weeks old German shepherd mongrel already shows an upward erection trend of the ears, with varying grades of erection during the day

Puppies often have characteristics that do not last beyond early puppyhood. Eye color often changes from blue to its adult color as the puppy matures. The coat color may change: Kerry Blue Terrier puppies have black coats at birth and change to blue with maturity, and Dalmatians are white and gain their spots with age. The ear shape will also often change, especially with erect-eared breeds such as the German Shepherd Dog which have soft ears at birth, but the cartilage strengthens with age. Labrador Retrievers and other swimming dogs, start of with a very fluffy puppy coat, and over time the water proof layer grows. Puppies that are going to grow into larger dogs, often will have over sized paws to begin with, and then the rest of them grow to fit.

Temperature regulation

It is a common misconception that dogs do not sweat. They do sweat, mainly through the footpads, but only a small fraction of a dog's excess heat is lost this way. Primarily, dogs

regulate their body temperature through panting. Panting moves cooling air over the moist surfaces of the tongue and lungs, rejecting heat to the atmosphere.

Dogs possess a rete mirabile, a complex of intermingled small arteries and veins, in the carotid sinus at the base of their neck. This acts to thermally isolate the head, containing the brain, the most temperature-sensitive organ, from the body, containing the muscles, where most of the heat is generated. The result is that dogs can sustain intense physical exertion over a prolonged time in a hot environment, compared to animals which lack this apparatus; thus, a dog chasing a jackrabbit through the desert may not be able to outrun the rabbit, but it can continue the chase until the rabbit slows due to overheating.

Chapter- 8

Equine Anatomy

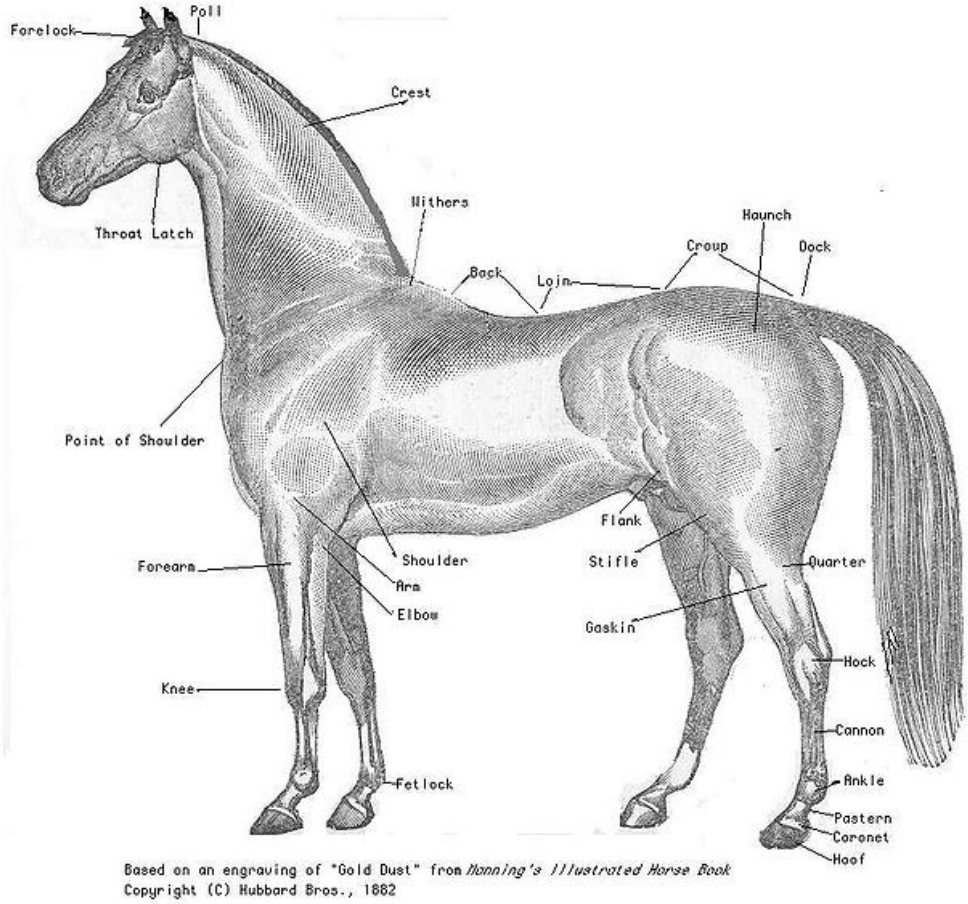

Parts of a Horse

Equine anatomy refers to the gross and microscopic anatomy of horses and other equids, including donkeys, and zebras. While all anatomical features of equids are described in the same terms as for other animals by the International Committee on Veterinary Gross

Anatomical Nomenclature in the book Nomina Anatomica Veterinaria, there are many horse-specific colloquial terms used by equestrians.

External anatomy

- **back**: the area where the saddle goes, begins at the end of the withers, extends to the last thoracic vertebrae. (Colloquially includes the loin or "coupling," though technically incorrect usage)
- **barrel**: the main body area of the horse, enclosing the rib cage and the major internal organs.
- **cannon** or **cannon bone**: The area between the knee or hock and the fetlock joint, sometimes called the "shin" of the horse, though technically it is the metacarpal III.
- **chestnut**: a callosity on the inside of each leg
- **chin groove**: the part of the horse's head behind the lower lip and chin. (the area that dips down slightly on the lower jaw). Area where the curb chain of certain bits is fastened.
- **coronet** or **coronary band**: The ring of soft tissue just above the horny hoof that blends into the skin of the leg.
- **crest**: the upper portion of the neck where the mane grows.
- **croup**: the topline of the horse's hindquarters, beginning at the hip, extending proximate to the sacral vertebrae and stopping at the dock of the tail (where the coccygeal vertebrae begin). Sometimes called "rump."
- **dock**: the point where the tail connects to the croup of the horse.
- **elbow**: The joint of the front leg at the point where the belly of the horse meets the leg. Homologous to the elbow in humans.
- **ergot**: a callosity on the back of the fetlock
- **fetlock**: Sometimes called the "ankle" of the horse, though it is not the same skeletal structure as an ankle in humans. Known to anatomists as the metacarpophalangeal (front) or metatarsophalangeal (hind) joint; homologous to the "ball" of the foot or the metacarpophalangeal joints of the fingers in humans.
- **flank**: Where the hind legs and the barrel of the horse meet, specifically the area right behind the rib cage and in front of the stifle joint.
- **forearm**: the area of the front leg between the knee and elbow. Consists of the fused radius and ulna, and all the tissue around these bones. Anatomically the antebrachium.
- **forelock**: the continuation of the mane, which hangs from between the ears down onto the forehead of the horse.
- **frog**: the highly elastic wedge-shaped mass on the underside of the hoof, which normally makes contact with the ground every stride, supports both the locomotion and circulation of the horse.
- **gaskin**: the large muscle on the hind leg, just above the hock, below the stifle. Homologous to the calf of a human.
- **girth' *or*** *heartgirth*: the area right behind the elbow of the horse, where the girth of the saddle would go, this area should be where the barrel is at its greatest diameter in a properly-conditioned horse that is not pregnant or obese.

- **hindquarters**: the large, muscular area of the hind legs, above the stifle and behind the barrel of the horse.
- **hock**: The tarsus of the horse (hindlimb equivalent to the human ankle and heel), the large joint on the hind leg.
- **hoof**: The foot of the horse. The hoof wall is the tough outside covering of the hoof that comes into contact with the ground. The hoof wall is, in many respects, a much larger and stronger version of the human fingernail.
- **jugular groove**: the line of indentation on the lower portion of the neck, can be seen from either side, just above the windpipe. Beneath this area run the jugular vein, the carotid artery and part of the sympathetic trunk.
- **knee**: the carpus of the horse (equivalent to the human wrist), the large joint in the front legs, above the cannon bone
- **loin**: the area right behind the saddle, going from the last rib of the horse to the croup. Anatomically approximate to the lumbar spine.
- **mane**: long and relatively coarse hair growing from the dorsal ridge of the neck, lying on either the left or right side of the neck).
- **muzzle**: the chin, mouth, and nostrils of the horse's face.
- **pastern**: The connection between the coronet and the fetlock. Made up of the middle and proximal phalanx.
- **poll**: commonly refers to the poll joint at the beginning of the horse's neck, immediately behind the ears, a slight depression at the joint where the atlas (C1) meets the occipital crest. Anatomically, the occipital crest itself is the "poll."
- **splints**: bones found on each of the legs, on either side of the cannon bone (8 total). Partially vestigial, these bones support the corresponding carpal bones in the forelimb, and the corresponding tarsal bones in the hindlimb. Anatomically referred to as Metacarpal/Metatarsal II (on the medial aspect (inside)) and IV (on the lateral aspect (outside)).
- **shoulder**: made up of the scapula and associated muscles. Runs from the withers to the point of shoulder (the joint at the front of the chest, i.e. the glenoid). The angle of the shoulder has a great effect on the horse's movement and jumping ability, and is an important aspect of equine conformation.
- **stifle**: Corresponds to the knee of a human, consists of the articulation between femur and tibia, as well as the articulation between patella and femur.
- **tail**: consists of both the living part of the tail (which consists of the coccygeal vertebrae, muscules, and ligaments), as well as the long hairs which grow from the living part
- **throatlatch**: The point at which the windpipe meets the head at the underside of the jaw.
- **withers**: the highest point of the thoracic vertebrae, the point just above the tops of the shoulder blades. Seen best with horse standing square and head slightly lowered. The height of the horse is measured at the withers in "hands."

Digestive system

Horses and other Equids evolved as grazing animals, adapted to eating small amounts of the same kind of food all day long. In the wild, the horse adapted to eating prairie grasses

in semi-arid regions and traveling significant distances each day in order to obtain adequate nutrition. Therefore, the digestive system of a horse is about 100 feet (30 m) long, and most of this is intestines.

The mouth

Digestion begins in the mouth, which is also called the "oral cavity." It is made up of the teeth, the hard palate, the soft palate, the tongue and related muscles, the cheeks and the lips. Horses also have three pairs of salivary glands, the parotid (largest salivary gland and located near the poll), submaxillary (located in the jaw), and sublingual (located under the tongue). Horses select pieces of forage and pick up finer foods, such as grain, with their sensitive, prehensile lips. The front teeth of the horse, called incisors, clip forage, and food is then pushed back in the mouth by the tongue, and ground up for swallowing by the premolars and molars.

The esophagus

The esophagus is about 4–5 feet in length, and carries food to the stomach. A muscular ring, called the cardiac sphincter, connects the stomach to the esophagus. This sphincter is very well developed in horses. This and the oblique angle at which the esophagus connects to the stomach explains why horses cannot vomit. The esophagus is also the area of the digestive tract where horses may suffer from choke.

The stomach

Horses have a relatively small stomach for their size, and this limits the amount of feed a horse can take in at one time. The average sized horse (800 to 1200 lb) has a stomach with a capacity of only four gallons, and works best when it contains about two gallons. Because the stomach empties when 2/3 full, whether stomach enzymes have completed their processing of the food or not, and doing so prevents full digestion and proper utilization of feed, continuous foraging or several small feedings per day are preferable to one or two large ones. The horse stomach consists of a non-glandular proximal region (saccus cecus), divided by a distinct border, the margo plicata, from the glandular distal stomach.

In the stomach, assorted acids and the enzyme pepsin break down food. Pepsin allows for the further breakdown of proteins into amino acid chains. Other enzymes include resin and lipase. Additionally, the stomach absorbs some water, as well as ions and lipid soluble compounds. The end product is food broken down into chyme. It then leaves the stomach through the pyloric valve, which controls the flow of food out of stomach.

The small intestine

The horse’s small intestine is 50 to 70 feet (21 m) long and holds 10 to 12 gallons. This is the major digestive organ, and where most nutrients are absorbed. It has three parts, the duodenum, jejunum and ileum. The majority of digestion occurs in the duodenum while

the majority of absorption occurs in the jejunum. Bile from the liver aids in digesting fats in the duodenum combined with enzymes from the pancreas and small intestine . Horses do not have a gall bladder, so bile flows constantly. Most food is digested and absorbed into the bloodstream from the small intestine, including proteins, simple carbohydrate, fats, and vitamines A, D, and E. Any remaining liquids and roughage move into the large intestine.

The large intestine

Cecum

The cecum is the first section of the large intestine. It is also known as the "water gut" or "hind gut." It is a cul-de-sac pouch, about 4 feet (1.2 m) long that holds 7 to 8 gallons. It contains bacteria that digest cellulose plant fiber through fermentation. These bacteria feed upon digestive chyme, and also produce certain fat-soluble vitamins which are absorbed by the horse. The reason horses must have their diets changed slowly is so the bacteria in the cecum are able to modify and adapt to the different chemical structure of new feedstuffs. Too abrupt a change in diet can cause colic, as the new food is not properly digested.

Colon

The large colon, small colon, and rectum make up the remainder of the large intestine. The large colon is 10–12 feet long and holds up to 20 gallons of semi-liquid matter. It is made up of the right lower (ventral) colon, the left lower (ventral) colon, the left upper (dorsal) colon, the right upper (dorsal) colon, and the transverse colon, in that order. Three flexures are also named; the sternal flexure, between right and left ventral colon; the pelvic flexure, between left dorsal and left ventral colon; the diaphragmatic flexure, between left dorsal and right dorsal colon. The main purpose of the large colon is to absorb carbohydrates, which were broken down from cellulose in the cecum. Due to its many twists and turns, it is a common place for a type of horse colic called an impaction.

The small colon is 10–12 feet in length and holds only 5 gallons of material. It is the area where the majority of water in the horse's diet is absorbed, and is the place where fecal balls are formed. The rectum is about one foot long, and acts as a holding chamber for waste matter, which is then expelled from the body via the anus.

Reproductive system

Mare

The reproductive system of the mare is responsible for controlling gestation, birth, lactation, as well as the estrous cycle and mating behavior of the mare. It lies ventral to the 4th or 5th lumbar vertebrae, although its position within the mare can vary depending on the movement of the intestines and distention of the bladder.

The mare has two ovaries, usually 7–8 cm in length and 3–4 cm thick, that generally tend to decrease in size as the mare ages. The ovaries connect to the fallopian tubes (oviducts), which serve to move the ovum from the ovary to the uterus. To do so, the oviducts are lined with a layer of cilia, which produce a current that flows toward the uterus. Each oviduct attaches to one of the two horns of the uterus, which are approximately 20–25 cm in length. These horns attach to the body of the uterus (18–20 cm long). Caudal to the uterus is the cervix, about 5–7 cm long, which enters the vagina. Usually 3.5–4 cm in diameter, it can expand to allow the passage of the foal. The vagina of the mare is 15–20 cm long, and is quite elastic, allowing it to expand. The vulva is the external opening of the vagina, and consists of the clitoris and two labia. It lies ventral to the rectum. The mare has two mammary glands, which are smaller in virgin mares. They have two ducts each, which open externally.

Stallion

The reproductive system of the stallion is responsible for the sexual behavior and secondary sex characteristics (such as a large crest) of the stallion. The external genitalia comprise:

- the testes, which are suspended horizontally within the scrotum. The testes of an average stallion are ovoids 8 to 12 cm long;
- the penis, within the prepuce, also known as the "sheath." When not erect, the penis is housed within the prepuce, 50 cm long and 2.5 to 6 cm in diameter with the distal end 15 to 20 cm. When erect, the penis doubles in length and thickness and the glans increases by 3 to 4 times. The urethra opens within the **urethral fossa**, a small pouch at the distal end of the glans.

The internal genitalia comprise the accessory sex glands:

- vesicular glands;
- prostate gland; and
- bulbourethral glands.

These contribute fluid to the semen at ejaculation, but are not strictly necessary for fertility

Teeth

A horse's teeth include incisors, premolars, molars, and sometimes canine teeth. A horse's incisors, premolars, and molars, once fully developed, continue to erupt throughout its lifetime as the grinding surface is worn down through chewing. Because of this pattern of wear, a rough estimate of a horse's age can be made from an examination of the teeth.

Feet/Hooves



1- Heel perioplium, 2-Bulb, 3-Frog, 4-Frog cleft, 5-Lateral groove, 6-Heel, 7-Bar, 8-Seat-of-corn, 9-Pigmented walls 10-Water line, 11-White line, 12-Apex of the frog, 13-Sole, 14-Toe, 15-How to measure hoof width (blue dotted line), 16-Quarter, 17-How to measure length (blue dotted line)

The hoof of the horse encases the second and third phalanx of the lower limbs, analogous to the fingertip or toe tip of a human. In essence, a horse travels on its "tiptoes." The hoof wall is a much larger, thicker and stronger version of the human fingernail or toenail, made up of similar materials, primarily keratin, a very strong protein molecule. The horse's hoof contains a high proportion of sulfur-containing amino acids which contribute to its resilience and toughness.

Skeletal system

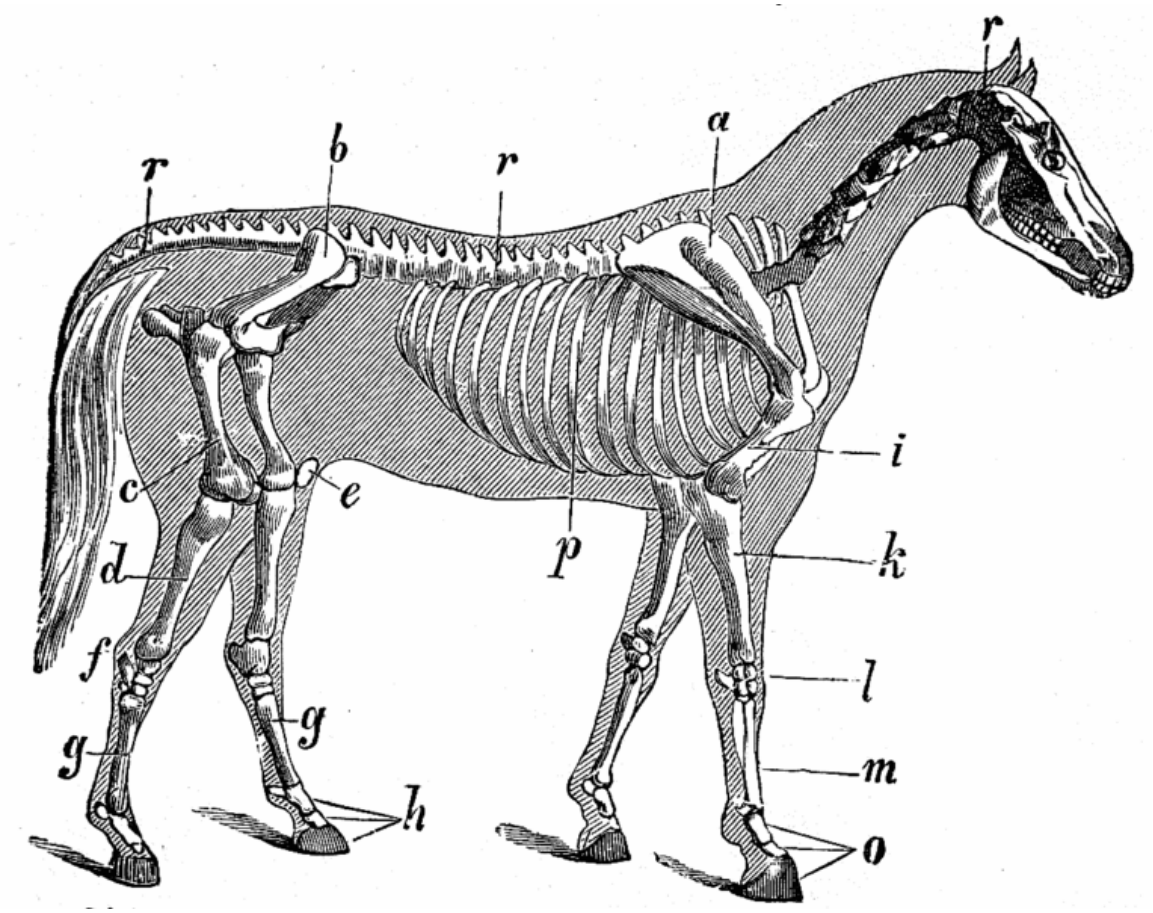

A horse's skeleton

The skeleton of the horse has three major functions in the body. It protects vital organs, provides framework, and supports soft parts of the body. Horses have 205 bones, which are divided into the appendicular skeleton (the legs) and the axial skeleton (the skull, vertebral column, sternum, and ribs). Both pelvic and thoracic limbs contain the same number of bones, 20 bones per limb. Bones are connected to muscles via tendons and other bones via ligaments. Bones are also used to store minerals, and are the site of red blood cell formation.

Ligaments and tendons

Ligaments

Ligaments attach bone to bone or bone to tendon, and are vital in stabilizing joints as well as supporting structures. They are made up of fibrous material that is generally quite strong. Due to their relatively poor blood supply, ligament injuries generally take a long time to heal.

Tendons

Tendons are cords of connective tissue attaching muscle to bone, cartilage or other tendons. They are a major contributor to shock absorption, are necessary for support of the horse's body, and translate the force generated by muscles into movement. Tendons are classified as flexors (flex a joint) or extensors (extend a joint). However, some tendons will flex multiple joints while extending another (the flexor tendons of the hind limb, for example, will flex the fetlock, pastern, and coffin joint, but extend the hock joint). In this case, the tendons (and associated muscles) are named for their most distal action (digital flexion).

Tendons form in the embryo from fibroblasts which become more tightly packed as the tendon grows. As tendons develop they lay down collagen, which is the main structural protein of connective tissue. As tendons pass near bony prominences, they are protected by a fluid filled synovial structure, either a tendon sheath or a sac called a bursa.

Tendons are easily damaged if placed under too much strain, which can result in a painful, and possibly career-ending, injury. Tendinitis is most commonly seen in high performance horses that gallop or jump. When a tendon is damaged the healing process is slow because tendons have a poor blood supply, reducing the availability of nutrients and oxygen to the tendon. Once a tendon is damaged the tendon will always be weaker, because the collagen fibres tend to line up in random arrangements instead of the stronger linear pattern. Scar tissue within the tendon decreases the overall elasticity in the damaged section of the tendon as well, causing an increase in strain on adjacent uninjured tissue.

Muscular system

When a muscle contracts, it pulls a tendon, which acts on the horse's bones to move them. Muscles are commonly arranged in pairs so that they oppose each other (they are "antagonists"), with one flexing the joint (a flexor muscle) and the other extending it (extensor muscle). Therefore, one muscle of the pair must be relaxed in order for the other muscle in the pair to contract and bend the joint properly. A muscle is made up of several muscle bundles, which in turn are made up of muscle fibers. Muscle fibers have myofibrils, which are able to contract due to actin and myosin. A muscle together with its tendon and bony attachments form an extensor or flexor unit.

Respiratory system and smell

The horse's respiratory system consists of the nostrils, pharynx, larynx, trachea, diaphragm, and lungs. Additionally, the nasolacrimal duct and sinuses are connected to the nasal passage. The horse's respiratory system not only allows the animal to breathe, but also is important in the horse's sense of smell (olfactory ability) as well as in communicating.

Circulatory system

The horse's circulatory system includes the four-chambered heart, averaging 8.5 lb (3.9 kg) in weight, as well as the blood and blood vessels. Its main purpose is to circulate blood throughout the body to deliver oxygen and nutrients to tissues, and to remove waste from these tissues. The frog (the V shaped part on the bottom of the horses hoof)is a very important part of the circulatory system. The frog consists of blood vessel filled tissue. When the horse steps, the ground pushes upward compressing the frog and causing the digital cushion to sqeeze the blood upward and back up the leg towards the heart. Helping the heart work against gravity.

The eye

A horse's eye

The horse has the largest eye of all land mammals, and is designed to help the horse as a prey animal. It provides the horse with a wide field of monocular vision, as well as good visual acuity and some ability to see color. Because the horse's vision is closely tied to his behavior, the horse's visual abilities are often taken into account when handling and training the animal.

Hearing

The pinna of a horse's ears can rotate in any direction to pick up sounds

The hearing of horses is good, superior to that of humans, and the pinna of each ear can rotate up to 180°, giving the potential for 360° hearing without having to move the head. Often, the eye of the horse is looking in the same direction as the ear is directed.

Chapter- 9

Suture (Anatomy)

In anatomy, a **suture** is a fairly rigid joint between two or more hard elements of an animal, with or without significant overlap of the elements.

Sutures are found in the skeletons or exoskeletons of a wide range of animals, in both invertebrates and vertebrates, from the Cambrian period to the present day. Sutures were and are formed by several different methods, and they exist between hard parts that are made from several different materials.

Vertebrate skeletons

These skeletons are made of bone, in which the main rigid ingredient is calcium phosphate.

Cranial sutures

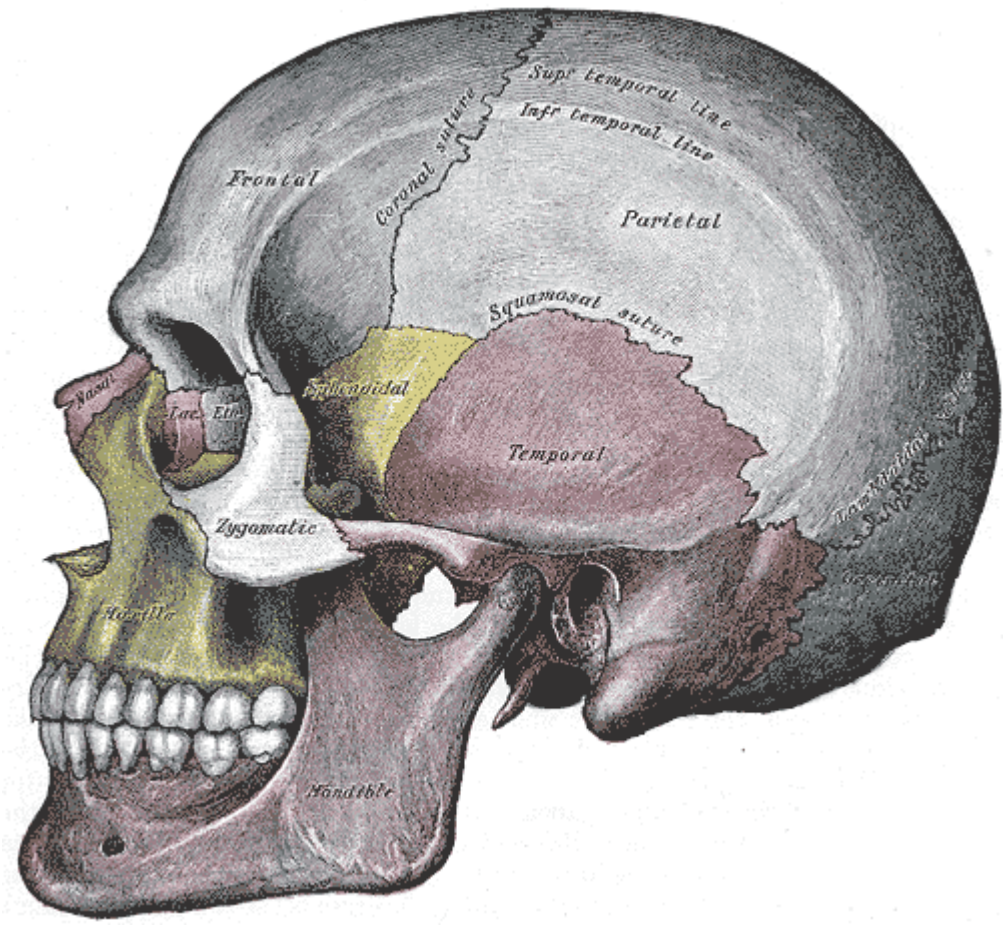

Side view of the skull. The wavy lines are cranial sutures.

The crania (brain cases) of most vertebrates consist of sets of bony plates held together by cranial sutures. These sutures are held together mainly by Sharpey's fibers which grow from each bone into the adjoining one.

Sutures in the ankles of land vertebrates

Crocodilian form of crurotarsal ankle. The astragalus (pink) is fixed to the tibia (green) by a suture. Adapted with permission from Palaeos

In the type of crurotarsal ankle which is found in crocodilians and some other archosaurs, the astragalus is fixed to the tibia by a suture, and the joint bends around a peg on the astragalus, which fits into a socket in the calcaneum.

Invertebrate exoskeletons

In molluscs

The shells of most molluscs are made of calcium carbonate (the main constituent of limestone and chalk), and of conchiolin, a protein.

Sutures in the shells of cephalopods



A variety of ammonite forms, from Ernst Haeckel's 1904 *Kunstformen der Natur* (Artforms of Nature).

In cephalopod mollusks which have external shells (e.g. *Nautilus*, ammonites), the shell is divided into compartments by septa ("partitions").

The septa are joined to the external shell by sutures formed by "repeated invagination" (they interlock like pieces of a jigsaw puzzle). The sutures are visible from the outside and often form complex and elaborate patterns.

The suture in the shells of gastropods

Two shells of *Papillifera bidens*, scale bar is in mm. These shells have 10 or 11 whorls and thus a very long suture, with an unusual sculpture of regularly placed papules along the suture itself.

Nearly all snail shells (except for the shells of limpets) can be visualized as a tube of increasing diameter, closed at the small end, and spirally wrapped around a central axis.

Each complete rotation of this spirally-arranged tube is called a whorl. The whorls of a snail shell usually overlap one another, forming a spire. Where the whorls overlap, there is usually a clear (if narrow) indentation. This indentation forms a visible line, which is continuous and reaches from the apex of the shell to the aperture; this line is the suture.

Details of the suture are often useful in discriminating one species from another, for example, sometimes the suture is channeled.

The suture also provides a sort of geographic marker from which one can refer to the positioning of patterning or sculpture, where that is relevant: for example some species have a darker or lighter subsutural band on the shell.

In arthropods

Sutures in the carapaces of trilobites

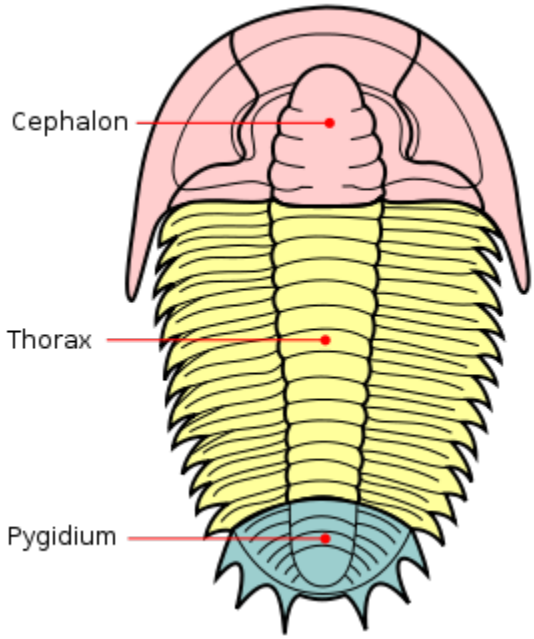

A trilobite's carapace consisted of calcite and calcium phosphate deposited on a lattice (framework) of chitin (a complex sugar).

The trilobite body is divided into three major sections: a cephalon (head section) with eyes, mouthparts and sensory organs such as antennae; a thorax of multiple segments which are similar to each other; and a pygidium, or tail section.

In many species the cephalon had sutures running from back to front round the outside edges of the eyes. These sutures divided the cephalon into 3 pieces.

The sutures in trilobites' cephalons were unusual because it seems their main function was to create *weaknesses* which made it easy for this part of the carapace ("armor") to split when the animal needed to molt.

Chapter- 10

Scale (Anatomy)

Keeled scales of a colubrid snake (Buff-striped Keelback; *Amphiesma stolatum*)

In most biological nomenclature, a **scale** (Greek λέπιδ *lepid*, Latin *squama*) is a small rigid plate that grows out of an animal's skin to provide protection. In lepidopteran (butterfly and moth) species, scales are plates on the surface of the insect wing, and

provide coloration. Scales are quite common and have evolved multiple times with varying structure and function.

Scales are generally classified as part of an organism's integumentary system. There are various types of scales according to shape and to class of animal.

Fish scales

Scales of Common Roach (*Rutilus rutilus*).

Fish scales are dermally derived, specifically in the mesoderm. This fact distinguishes them from reptile scales paleontologically. Genetically, the same genes involved in tooth and hair development in mammals are also involved in scale development.

Cosmoid scales

True cosmoid scales can only be found on the extinct Crossopterygians. The inner layer of the scale is made of lamellar bone. On top of this lies a layer of spongy or vascular bone and then a layer of dentine-like material called cosmine. The upper surface is keratin. The coelacanth has modified cosmoid scales that lack cosmine and are thinner than true cosmoid scales.

Ganoid scales

Ganoid scales can be found on gars (family Lepisosteidae) and bichirs and reedfishes (family Polypteridae). Ganoid scales are similar to cosmoid scales, but a layer of ganoin lies over the cosmine layer and under the enamel. They are diamond-shaped, shiny, and hard.

Placoid scales

Placoid scales are found on cartilaginous fish including sharks. These scales, also called denticles, are similar in structure to teeth.

Leptoid scales

Leptoid scales are found on higher-order bony fish. As they grow they add concentric layers. They are arranged so as to overlap in a head-to-tail direction, like roof tiles, allowing a smoother flow of water over the body and therefore reducing drag. They come in two forms:

- **Cycloid scales** have a smooth outer edge, and are most common on fish with soft fin rays, such as salmon and carp.
- **Ctenoid scales** have a toothed outer edge, and are usually found on fish with spiny fin rays, such as bass and crappie.

Reptilian scales

Reptile scale types include: cycloid, granular (which appear bumpy), and keeled (which have a center ridge).

The scales of all reptiles have an epidermal component (what one sees on the surface), but many lizards have osteoderms underlying the epidermal scale, as do crocodilians and turtles. Such scales are more properly termed scutes. Snakes, tuataras and many lizards lack osteoderms. All reptilian scales have a dermal papilla underlying the epidermal part, and it is there that the osteoderms, if present, would be formed.

Arthropod scales



Scales on the wing of a Heath Fritillary (*Melitaea athalia*)

Butterflies and moths - the order Lepidoptera (Greek "scale-winged") - have membranous wings covered in delicate, powdery scales, which are modified setae. Each scale consists of a series of tiny stacked platelets of organic material, and butterflies tend to have the scales broad and flattened, while moths tend to have the scales narrower and more hair-like. Scales are usually pigmented, but some types of scales are metallic, or iridescent, without pigments; because the thickness of the platelets is on the same order as the wavelength of visible light the plates lead to structural coloration and iridescence through the physical phenomenon described as thin-film optics. The most common color produced in this fashion is blue, such as in the *Morpho* butterflies. Other colors can be seen on the Sunset moth.